


EHRA expert consensus statement and practical guide on optimal implantation technique for conventional pacemakers and implantable cardioverter-defibrillators: endorsed by the Heart Rhythm Society (HRS), the Asia Pacific Heart Rhythm Society (APHRS), and the Latin-American Heart Rhythm Society (LAHRS)

Haran Burri  (Chair)^{1*}, **Christoph Starck** (Co-chair)^{2,3,4}, **Angelo Auricchio**⁵, **Mauro Biffi**⁶, **Mafalda Burri**⁷, **Andre D'Avila** (LAHRS representative)^{8,9}, **Jean-Claude Deharo**¹⁰, **Michael Glikson**¹¹, **Carsten Israel**¹², **Chu-Pak Lau** (APHRS representative)¹³, **Christophe Leclercq**¹⁴, **Charles J. Love** (HRS representative)¹⁵, **Jens Cosedis Nielsen**¹⁶, and **Kevin Vernooy**^{17,18}

Reviewers: Nikolaos Dages (review coordinator)¹⁹, **Serge Boveda** (review coordinator)²⁰, **Christian Butter**²¹, **Eloi Marijon**²², **Frieder Braunschweig**²³, **Georges H. Mairesse**²⁴, **Marye Gleva**²⁵, **Pascal Defaye**²⁶, **Francesco Zanon**²⁷, **Nestor Lopez-Cabanillas**²⁸, **Jose M. Guerra**²⁹, **Vassilios P. Vassilikos**^{30,31}, and **Mario Martins Oliveira**³²

¹Department of Cardiology, University Hospital of Geneva, Rue Gabrielle-Perret-Gentil 4, 1211 Geneva, Switzerland; ²Department of Cardiothoracic and Vascular Surgery, German Heart Center, Berlin, Augustenburger Pl. 1, 13353 Berlin, Germany; ³German Center of Cardiovascular Research (DZHK), Partner Site Berlin, Berlin, Germany; ⁴Steinbeis University Berlin, Institute (STI) of Cardiovascular Perfusion, Berlin, Germany; ⁵Fondazione Cardiocentro Ticino, Via Tesserete 48, CH-6900 Lugano, Switzerland; ⁶Azienda Ospedaliero-Universitaria di Bologna, Policlinico S.Orsola-Malpighi, Università di Bologna, Bologna, Italy; ⁷Division of Scientific Information, University of Geneva, Rue Michel Servet 1, 1211 Geneva, Switzerland; ⁸Serviço de Arritmia Cardíaca—Hospital SOS Cardio, 2 Florianópolis, SC, Brazil; ⁹Harvard-Thorndike Electrophysiology Institute, Beth Israel Deaconess Medical Center, Harvard Medical School, Boston, MA, USA; ¹⁰Hôpital de la Timone, 264 rue St Pierre, 13005 Marseille, France; ¹¹Shaare Zedek Medical Center, Jerusalem, Israel; ¹²Department of Cardiology, Bethel-Clinic Bielefeld, Burgsteig 13, 33617, Bielefeld, Germany; ¹³Division of Cardiology, University of Hong Kong, Queen Mary Hospital, Pok Fu Lam, Hong Kong; ¹⁴Université de Rennes I, CICIT 804, Rennes, CHU Pontchaillou, Rennes, France; ¹⁵Johns Hopkins Hospital and School of Medicine, Baltimore, MD, USA; ¹⁶Department of Cardiology, Aarhus University Hospital, Palle Juul-Jensens Blvd. 161, 8200 Aarhus, Denmark; ¹⁷Department of Cardiology, Cardiovascular Research Institute Maastricht (CARIM), Maastricht University Medical Center, Maastricht, The Netherlands; ¹⁸Department of Cardiology, Radboud University Medical Center (Radboudumc), Nijmegen, The Netherlands; ¹⁹Department of Electrophysiology, Heart Center Leipzig at University of Leipzig, Leipzig, Germany; ²⁰Heart Rhythm Department, Clinique Pasteur, 31076 Toulouse, France; ²¹Department of Cardiology, Heart Center Brandenburg, Chefarzt, Abteilung Kardiologie, Berlin, Germany; ²²University of Paris, Head of Cardiac Electrophysiology Section, European Georges Pompidou Hospital, 20 Rue Leblanc, 75908 Paris Cedex 15, France; ²³Karolinska University Hospital, Norrbacka S3:00, 17176 Stockholm, Sweden; ²⁴Department of Cardiology—Electrophysiology, Cliniques du Sud Luxembourg—Vivalia, rue des Deportes 137, BE-6700 Arlon, Belgium; ²⁵Washington University in St Louis, St Louis, MO, USA; ²⁶CHU Grenoble Alpes, Unite de Rythmologie, Service De Cardiologie, CS10135, 38043 Grenoble Cedex 09, France; ²⁷Arrhythmia and Electrophysiology Unit, Department of Cardiology, Santa Maria della Misericordia Hospital, Rovigo, Italy; ²⁸Adventist Cardiovascular Institute of Buenos Aires, Buenos Aires, Argentina; ²⁹Department of Cardiology, Hospital de la Santa Creu i Sant Pau, Universitat Autònoma de Barcelona, CIBERCV, Barcelona, Spain; ³⁰Medical School, Aristotle University of Thessaloniki, Thessaloniki, Greece; ³¹3rd Cardiology Department, Hippokrateio General Hospital, Thessaloniki, Greece; and ³²Department of Cardiology, Hospital Santa Marta, Rua Santa Marta, 1167–024 Lisbon, Portugal

Abstract

With the global increase in device implantations, there is a growing need to train physicians to implant pacemakers and implantable cardioverter-defibrillators. Although there are international recommendations for device indications and programming, there is no consensus to date regarding implantation technique. This document is founded on a systematic literature search and review, and on consensus from an international task force. It aims to fill the gap by setting standards for device implantation.

Keywords

Pacemaker • Implantable cardioverter-defibrillator • Implantation • Recommendations • Consensus document

Introduction

Scope of the document

According to the 2017 European Heart Rhythm Association (EHRA) white book, pacemaker (PM) implantations have increased by 20% and implantable cardioverter-defibrillator (ICD) by 44% over a 10-year period in the European Society of Cardiology (ESC) member countries.¹ Therefore, there is a growing need to train device implanters. Proper training in implantation technique results in improved patient outcome, as demonstrated by lower rates of in-hospital^{2,3} and long-term⁴ complications in procedures performed by electrophysiologists compared to other specialties. The core curriculum for the heart rhythm specialist⁵ and the EHRA certification exam provide a framework for required training duration, procedural volume, and knowledge assessment, but do not specifically address proficiency in device implantation technique. An EHRA survey on preferred tools and techniques for implantation of cardiac electronic devices showed considerable heterogeneity in practices across Europe.⁶ There is, therefore, an unmet need to define best practice for device implantation. The aim of this document is to provide up-to-date recommendations for optimal implantation technique of standard PMs and ICDs, based upon published evidence and expert consensus, in order to provide guidance for training and clinical practice, and ultimately to improve patient outcome. Specific domains, such as leadless pacing, conduction system pacing, cardiac resynchronization therapy (CRT), sub-cutaneous ICDs, and device therapy in children and patients with congenital heart disease are not covered here.

Methodology

This EHRA consensus document is based on a systematic literature search and review. M.B. searched PubMed, Embase, Web of Science, and Cochrane electronic databases for full-text original articles and case reports in English language published between 1 January 2000 and 20 March 2020 relating to transvenous PM and ICD implantation. Additional references were hand-searched and retrieved by checking reference lists by H.B. and C.S. From 4108 retrieved articles uploaded to the Covidence platform (Melbourne, Australia), 477 articles were finally selected by H.B. and C.S. (for details see [Supplementary material online, Appendix](#)).

Recommendations are based upon strength of evidence and consensus as outlined in *Table 1*. All recommendations were subjected to voting and required at least 75% agreement to reach consensus for green and red hearts.

General considerations

Preoperative preparation

As a first step, it is important to re-evaluate the indication and to perform a risk-benefit analysis for every patient. This requires a full medical history, review of laboratory results and imaging studies, and knowing current guidelines. A list of elements to consider is shown in *Table 2*.




As a prerequisite for cardiac implantable electronic device (CIED) implantation the patient should be free of active infection and afebrile for >24 h. Antibiotic prophylaxis should be given in all cases (e.g. cephazolin 1–2 g or flucloxacillin 1–2 g within 1 h of incision, or, in case of allergy or high probability of resistant pathogens, vancomycin 15 mg/kg within 90–120 min). Specific measures to prevent CIED infection are covered in detail in a recent EHRA consensus document.⁷

Patients on anticoagulation and/or antiplatelet drugs require special considerations, as pocket haematoma increases the risk for infection.^{7,8} In patients with non-rheumatic atrial fibrillation (AF) and a low risk for thrombo-embolic events (CHA₂DS₂VASc score < 3) perioperative interruption of anticoagulation is an option.⁹ In all other patients, uninterrupted oral anticoagulation (aiming for international normalized ratio <3.0 or <3.5 in case of a mechanical valve prosthesis) is preferable to heparin-bridging (especially if using low molecular weight heparin), as it reduces the risk of haematoma.^{9–11} In the BRUISE-CONTROL 2 study,¹¹ patients on a direct oral anticoagulant with a CHA₂DS₂VASc score of ≥2 had no difference in haematoma with or without interruption of therapy (doses including the morning dose were taken in the latter group). The conclusion of the study is that either management strategy is reasonable and should be based upon clinical judgement. Perioperative management of anticoagulants and/or antiplatelet drugs¹² is shown in *Table 3*.

Operative environment

The operative room/catheterization or electrophysiology laboratory must be ventilated with >15 air changes/h (ideally 20–25 changes/h).^{13,14} The utility of laminar airflow on surgical site infections remains controversial.^{14,15} Operators should ensure that all required hardware and equipment is available before the intervention (see *Table 4*). Checklists and surgical ‘time-out’ are useful to avoid errors. Anaesthesia support should be readily available on the premises due to potentially life-threatening complications, to assist if necessary with analgesia or haemodynamic/respiratory support.

Table 1 Categories of consensus statements

Consensus statement	Definition	Symbol
Recommended/indicated or 'should do this'	Scientific evidence that a treatment or procedure is beneficial and effective, or is strongly supported by authors' consensus.	
May be used or recommended	General agreement and/or scientific evidence favour the usefulness/efficacy of a treatment or procedure	
Should NOT be used and is NOT recommended	Scientific evidence or general agreement not to use or recommend a treatment or procedure	

Evidence: E, expert opinion; M, meta-analysis; O, observational studies; R, randomized trials.

Table 2 Preoperative preparation: elements to consider

<i>History</i>
Symptoms
Hobbies (e.g. hunting etc.)/profession (risk of trauma, lead crush, EMI, special permits etc.)
Medication (anticoagulants, antiplatelet drugs etc.)
For replacements/revisions/upgrades: connector types, venous obstruction
Comorbidities (diabetes → adapt insulin dose, early timing of procedure; prior chest radiotherapy, ²³⁶ treatment of breast cancer, ^{236,237} haemodialysis → contralateral implantation; dementia → measures for wound care; COPD → prudent oxygen administration due to risk of hypercapnia; presence of indwelling catheters or pacing leads, history of cardiac surgery, history of previous CIED infection, etc.)
Evaluation of patients concerns and preferences (e.g. cosmetic aspects)
Requirement for MRI-conditional (including 1.5 T or 3 T conditional)
Allergies (antibiotics, iodine, device components e.g. silicone, titanium, ²³⁸⁻²⁴¹ etc.)
Drug intolerance (opiates, sedatives)
<i>Test results</i>
Blood tests (haematology, INR if on VKA, renal function, electrolytes)
ECG (underlying rhythm; LBBB → risk of traumatic heart block or requirement for CRT)
Holter if available (sinus function, AV conduction disease)
Exercise test if available (exercise capacity, chronotropic incompetence, atrioventricular conduction)
View echocardiogram images if available (LVEF, chamber size, evidence of PLSVC with dilated CS, severe tricuspid regurgitation)
Chest X-ray if available (morphological abnormalities, for comparison with post-operative X-ray)
<i>Other considerations</i>
Timing (fasting in diabetic patients, dialysis etc.)
Required skills/experience of the operator
Availability of required material and adequate fluoroscopy
Availability of required support personnel
Operative environment

AV, atrioventricular; CIED, cardiac implantable electronic device; COPD, chronic obstructive pulmonary disease; CRT, cardiac resynchronization therapy; CS, coronary sinus; ECG, electrocardiogram; EMI, electromagnetic interference; INR, international normalized ratio; LBBB, left bundle branch block; LVEF, left ventricular ejection fraction; MRI, magnetic resonance imaging; PLSVC, persistent left superior vena cava; VKA, vitamin K antagonist.

Staff, training, and qualifications

Team members should be proficient with sterile techniques and practice. Poor adherence to these standards results in higher rates of surgical site infections.¹⁶ The operator should have EHRA level 2 or national certification, equivalent expertise, or be adequately supervised if in training. Procedural volume is also important to maintain expertise; operators or centres with <50 implantations/year have been shown to have higher complication rates.^{17,18}

In addition to the operator, at least one non-scrubbed nurse or allied professional proficient with supporting device implantation and procedural sedation should be present in the room, but the presence

of unnecessary personnel should be avoided. All personnel should be trained with radioprotection and the operator should strive to minimize radiation exposure.¹⁹⁻²¹ The operator, or another physician present on site, should be able to perform emergency pericardiocentesis and cardiopulmonary resuscitation manoeuvres.

Specific operative steps

A checklist covering the different operative steps is provided in the [Supplementary material online](#), *Appendix*, as are links to online video

Table 3 Perioperative management of anticoagulants and antiplatelet drugs

Dual antiplatelet therapy		DOAC	VKA	OAC + antiplatelet
ACS at PCI or other high-risk features^a				
No	Yes			
<1 month	<6 months	Continue or interrupt as per operator preference and/or thromboembolic risk	Continue (or consider interrupting without heparin bridging if $CHA_2DS_2VASc < 3$)	Continue OAC (VKA or DOAC)
Continue DAPT	Continue DAPT (may consider discontinuing P2Y ₁₂ inhibitor if 1–6 months)			
>1 month	>6 months	If interruption, then based on CrCl and specific DOAC		Discontinue antiplatelet per patient specific risk/benefit analysis
Continue aspirin + Discontinue P2Y ₁₂ inhibitors ^b	Discontinue P2Y ₁₂ inhibitors ^b			

Recommendations for P2Y₁₂ based upon reference,¹² for DOAC on reference,¹¹ VKA on reference.⁹

^aPrior stent thrombosis on adequate antiplatelet therapy; stenting of the last remaining patent artery; diffuse multivessel disease especially in diabetic patients; creatinine clearance <60 mL/min; ≥3 stents implanted; ≥3 lesions treated; bifurcation with 2 stents implanted; total stent length >60 mm; treatment of chronic total occlusion.

^bTicagrelor ≥3 days prior surgery; Clopidogrel ≥5 days prior surgery; Prasugrel ≥7 days prior surgery. Restart as soon as possible (within 48 h).

ACS, acute coronary syndrome; CrCl, creatinine clearance; DAPT, dual antiplatelet therapy; DOAC, direct oral anticoagulant; OAC, oral anticoagulation; PCI, percutaneous coronary intervention; VKA, vitamin K antagonist.

tutorials, which provide practical tips on performing selected techniques. Measures to prevent infection have been recently covered in a consensus document⁷ and will not be repeated here. Surgical hand preparation with antimicrobial soap and water or alcohol-based hand rubs should be performed according to the World Health Organization global guidelines for prevention of surgical site infection (see [Supplementary material online, Appendix](#)).¹⁴

Left-sided implants are usually favoured due to this being the non-dominant side [and also due to lower defibrillation thresholds (DFT) for ICDs]. The decision should be individualized and account for specific requirements (see [Table 2](#)).

Incision and pocket creation

After prepping the skin, local anaesthesia is mostly performed using 1% lidocaine (maximum dose 4.5 mg/kg or 300 mg) which may also be used semi-diluted to administer a larger volume over a greater area,²² or mixed with a long-acting local anaesthetic e.g. bupivacaine 0.25% or ropivacaine 0.5%. The use of epinephrine-containing local anaesthetics has been associated with a higher incidence of haematomas and should be avoided.²³ Deep sedation or general anaesthesia may be required in agitated patients, or in specific instances (e.g. lead tunnelization or submuscular pockets). A horizontal incision inferior and parallel to the clavicle, or an oblique incision slightly medial or along the deltopectoral groove may be performed according to operator preference, and have shown to yield similar scar healing (see [Supplementary material online, Video S1](#)).²⁴ The oblique incision may provide better access for cephalic vein cutdown, but being relatively lateral, the pocket should be prepared more medially with enough spacing to avoid conflict with the shoulder.

Many operators prefer to create the pocket at the beginning of the procedure for new implants, as local anaesthesia may be more effective at this stage, and bleeding can be monitored during the intervention. It is important to perform dissection down to the subfascial plane, even when a generous amount of adipose tissue is present (see [Supplementary material online, Video S2](#)). With the relatively small size of current generators, the majority of operators chose to implant PMs and ICDs in a subcutaneous (subfascial prepectoral)

pocket. A submuscular pocket may be considered in thin patients who are at risk for pocket erosion, for cosmetic reasons, or in case of Twiddler's syndrome. It is important to respect anatomical planes (i.e. between the pectoralis major and minor muscles) and not to create an intramuscular pocket to avoid undue tissue damage and bleeding (see [Supplementary material online, Video S3](#)). Submammary^{25,26} and axillary²⁷ pockets have also been performed for cosmetic reasons but are rarely used.

Venous access

Due to variations in patient anatomy and for the reasons outlined below, implanters should be proficient with cephalic venous cutdown, axillary and subclavian vein puncture. It is useful to place an ipsilateral intravenous line in case a venogram is required; this does not increase the risk of infection.²⁸ The use of micropuncture kits allows vascular access with a small 21 gauge needle as opposed to the standard method, which requires an 18 gauge needle and can be used to decrease severity of complications due to inadvertent arterial or pleural puncture.

Cephalic venous cutdown

The cephalic vein is the first approach in 60% of centres according to the EHRA survey.⁶ After distal ligation, the vein may be incised followed by direct introduction of the lead (see [Figure 1](#)) or a puncture may be performed with introduction of a sheath (see [Supplementary material online, Video S4](#)). In case of difficulty inserting the lead or if more than one lead is implanted, using a guidewire and introducer sheath is helpful.

Cephalic vein access has the advantage of avoiding pneumothorax and reducing the risk of lead dysfunction compared to subclavian puncture [odds ratio (OR) 0.25, 95% confidence interval (CI) 0.13–0.51, $P < 0.001$].²⁹ Successful cannulation is reported in approximately 60–80% of patients,^{30–33} but may reach >90% with the help of hydrophilic guidewires or use of retro-pectoral veins.^{34–36} Hydrophilic angulated guidewires are useful for crossing venous valves and to steer access towards the subclavian vein when the lead tracks towards the arm (asking the patient to lift the shoulder while

Table 4 Required equipment and useful accessories for cardiac implantable electronic device implantation

Equipment	Purpose
Programmer (company specific) and pacing sense analyser with sterile cables	Lead testing and device programming
Fluoroscopy with >40° viewing angles	Correct positioning of leads
Electrocautery (optionally plasma electrocautery)	Haemostasis. Plasma electrocautery to avoid lead damage when freeing leads
Monitoring of cardiac rhythm, cuff blood pressure and pulse oximetry, EtCO ₂	Monitoring of vital signs
Oxygen supply, suction, bag-ventilation equipment	Handling of respiratory emergencies
Emergency cart with drugs and intubation material (rapidly available on site)	Management of cardiovascular and rhythm emergencies
External defibrillator (preferably biphasic) capable of providing temporary transcutaneous pacing (placed in an antero-posterior position)	Cardioversion/defibrillation, temporary transcutaneous pacing
Echocardiography (available rapidly on site)	Confirmation of tamponade
<i>Accessories</i>	
Long sheaths (7–9 F) e.g. 23 cm	Placement of leads across vein stenoses
Hydrophilic 0.035" guidewire	Crossing of vein stenoses and tortuous vessels
Extra-stiff 0.035" guidewire	Provide support to place introducer sheaths across stenotic or tortuous vessels
Lead stylets (e.g. 65 cm)	Backup in case of kinking of stylets provided with the lead
Tunnelization tools (e.g. trocar, chest tube etc)	Allows contralateral implantation with tunnelization to pocket in case of vein occlusion in upgrades/revisions
Non-dynamometric wrench (Allen key)	Freeing of frozen setscrews
Lead insulation repair kit (silicone sleeves, glue)	Repair of insulation breach identified at generator change/lead revision
Lead splicing adaptor (e.g. Medtronic 5866–9M)	Salvage of fractured pacing lead
Lead caps	Capping of abandoned leads
Connector plug (IS-1, DF-1)	Plugging unused generator ports
Lead extenders	Tunneling to contralateral pocket
Sterile lubricant, pure alcohol	Freeing of frozen leads at generator change
Pericardial puncture tray assembling all required accessories (available in the room)	Emergent pericardiocentesis

steering the lead or wire can also help). Introduction of up to three leads using introducer sheaths is possible in the great majority of patients, but in rare instances, a separate puncture for venous access is required.³⁶ Bleeding complications are not significantly different compared to subclavian access.^{29,37} Supra-clavicular course of the vein is a rare variant that should be recognized by fluoroscopy and by palpating the lead over the clavicle.^{38,39} In this rare instance, alternative routes should be used to avoid discomfort or lead complications.

Intra-thoracic subclavian vein puncture

Subclavian puncture was initially popular due to its high success rate (approximately 95%^{32,40,41}) but carries a risk of pneumothorax (approximately 1–2% of patients^{40,42,43}) and lead failure due to subclavian crush (see *Figure 2*).^{29,32,44–46} Friction with the clavicle, subclavius muscle or costo-clavicular ligament may also restrict lead manipulation and positioning. Subclavian access has been associated with a higher risk of bleeding complications in patients receiving antiplatelet drugs.⁴⁷ Other rare complications include arterio-venous fistula,⁴⁸ transient phrenic nerve palsy due to local anaesthesia,⁴⁹ and thoracic duct injury. For these reasons, it is recommended that intrathoracic subclavian vein puncture is not used as a first-line approach, but as a

bailout technique in case other routes have failed, or for venous access medial to occlusions.⁵⁰ The puncture should be as lateral as possible to avoid lead crush (see [Supplementary material online, Video S5](#)). It may be performed using only bony landmarks (below and slightly lateral to the most prominent part of the clavicle for the puncture site, directing the needle towards the sternal notch) or under fluoroscopy aiming towards the middle of the clavicular head. A venogram may be useful to target the vein and reduce the risk of complications. For dual-chamber devices, separate punctures may reduce the risk of bleeding and of lead dysfunction due to crowding, but this has not been proven and may expose the patient to increased risk of pneumothorax compared to a single puncture, especially in case of difficult access or risky anatomy [e.g. low body mass index (BMI) or chronic obstructive pulmonary disease].

Extra-thoracic subclavian and axillary vein puncture

The axillary vein becomes the extra-thoracic subclavian vein as it crosses over the inferior border of the first rib. These segments are considered analogous for the purposes of this document. Axillary vein puncture is being increasingly adopted following the introduction of new techniques which have improved its safety and efficacy, as

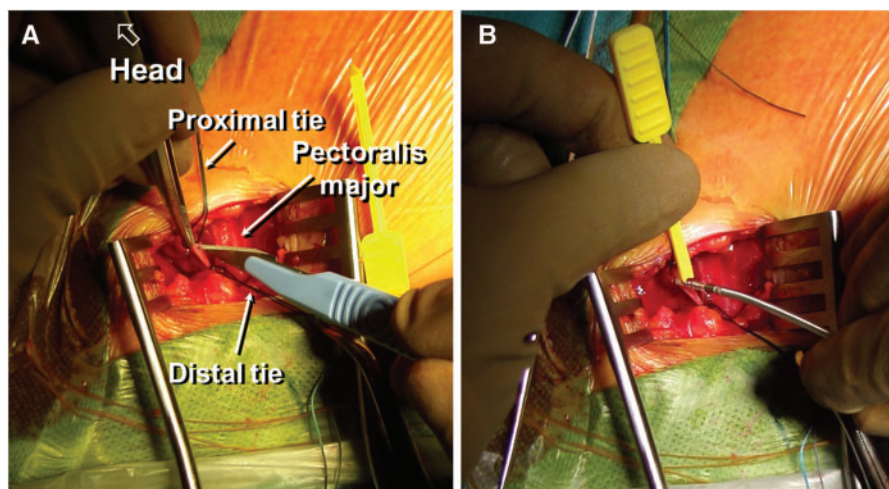


Figure 1 Cephalic venous cutdown (right-sided). (A) Dissection to the deltopectoral groove, with exposure of the cephalic vein to which are looped a proximal (top) and distal tie (bottom). The distal tie is fastened and gently pulled with a clamp. The anterior part of the vein is lifted by forceps and a venotomy made with a scalpel or scissors to expose the lumen of the vein (a common mistake is to incise only to the adventitia). Alternatively, the vein may be punctured with a needle or venous catheter to introduce a guidewire. (B) The vein lifter (yellow tool) is used to introduce the lead (alternatively a guidewire can be inserted to use a sheath). If blood prevents visualization of the lumen, the proximal tie can be pulled gently to prevent backflow and then released once the lead is inserted.

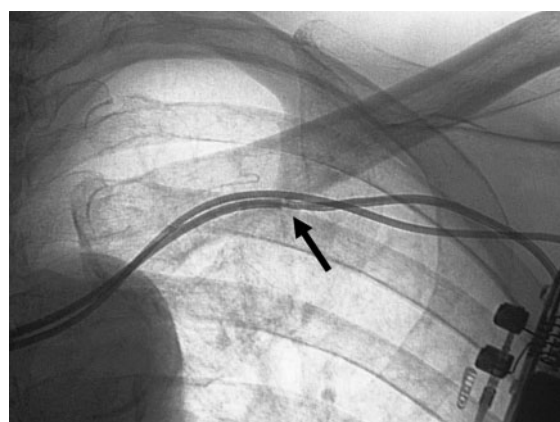


Figure 2 Lead crush with subclavian vein puncture. Patient with a single chamber pacemaker who had lead failure due to subclavian crush (arrow). An additional lead was implanted by axillary vein puncture.

well as evidence of superior success rates compared to cephalic venous cutdown^{30,32,33} and improved outcome compared to subclavian vein puncture, especially with regard to reducing the risk of lead failure.^{32,40,46} The risk of bleeding is not different compared to cephalic access.³⁷

A variety of techniques have been described using anatomic landmarks,^{51–53} a venogram,^{30,32,54,55} a guidewire from the antecubital vein as a roadmap,⁵⁵ fluoroscopic bony landmarks (most often the outer border of the first rib)^{31,33,54,56–58} or ultrasound,^{41,59–64} with

approximately 95% success. A useful technique is to access the axillary vein using a 35° caudal fluoroscopic view and to aim the region overlying the outer border of the first rib (see [Figure 3](#) and [Supplementary material online, Video S6](#)), which has been shown to be successful in 96% of cases.⁵⁸ This exposes the subclavian space and the anterior outline of the lungs, thereby eliminating the risk of pneumothorax if the technique is properly performed. The same view may be used with a venogram if the vein is not accessed using fluoroscopic landmarks only. A shallow approach using this technique also reduces X-ray exposure to the hands as well as flexion stress on the lead (which may be an issue with a steep angle for ‘walking’ the puncture needle on the first rib).

Ultrasonography is likely to be increasingly adopted as it reduces X-ray exposure to the operator (see [Supplementary material online, Video S7](#)), has a self-learned success rate of 97.7%,⁶⁵ and its intra-operative use is facilitated by the advent of wireless devices.⁶⁰ It also allows to concomitantly perform pectoral nerve block.⁶⁶

In some cases, narrowing of the axillary vein may occur due to compression by haematoma induced by inadvertent arterial puncture or bleeding from the muscle.

Troubleshooting venous access

In patients previously implanted with leads, venous stenosis of >75% is found in 6–21% of patients and vein occlusion in 6–26%.^{67–69} Superficial collateral veins may be visible on the patient’s chest, but do not necessarily indicate obstruction,⁷⁰ and most patients have no complaints. In patients requiring an upgrade, it is very useful to perform a venogram prior to skin incision to confirm patency using the same view as for venous access (e.g. 35° caudal tilt) to plan the procedure. Peripheral venography may however overestimate occlusion with collaterals, as more selective dye injection via a dilator can reveal

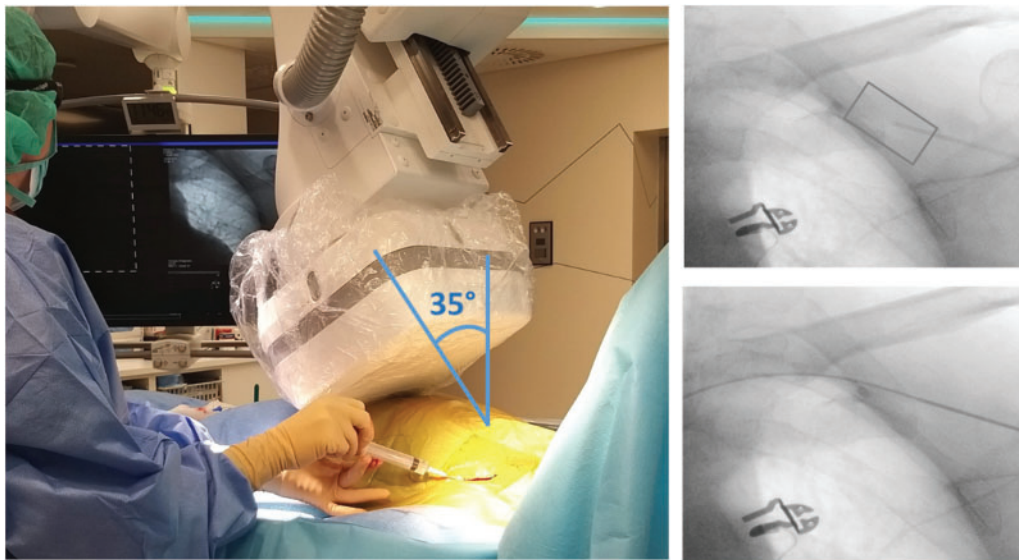


Figure 3 Axillary vein puncture using fluoroscopic landmarks. The caudal tilt exposes the outer margin of the lung, allowing safe puncture and minimizing risk of pneumothorax. The target site is shown in the rectangle (top right). After successful puncture, a guidewire is inserted and the needle entry site in the vein can be appreciated (bottom right).

flow through the lesion in approximately two-thirds of these cases.⁷¹ Hydrophilic 0.035" guidewires, hydrophilic catheters, and long sheaths are very useful to cross stenoses. Hydrophilic wires should be handled carefully to avoid perforation. More medial punctures^{50,72,73} or venoplasty^{69,71,74} may be performed for occlusions. For upgrades, contralateral venous access with subcutaneous tunnelization to the pocket may be performed, e.g. with a trochar and a chest tube.⁷⁵ Other more invasive options are lead extraction and the 'inside out' technique⁷⁶ which need to be performed in specialized centres.

In patients with pre-existing leads which are to be abandoned or explanted, the retained wire under lead insulation technique can be used to gain venous access if the old lead is able to be pushed a few centimetres into the vein.⁷⁷

Alternative routes for venous access as a bailout solution include the internal/external jugular vein,⁷⁸ and iliofemoral access.^{79,80} Leadless PMs, subcutaneous ICDs, or epicardial leads are options which should be considered in case of venous access issues. Lead extraction may also be an option to gain venous access (either using extraction sheaths via a superior approach, or a femoral approach with a retained guidewire in the lead lumen).

The azygous vein may be unintentionally cannulated by the guidewire or the lead. This can be recognized by the posterior course of the vein just above the right main bronchus (*Figure 4*).

A persistent left superior vena cava (PLSVC) is encountered in up to 0.5% of patients.⁸¹ This structure usually regresses to become the Marshall vein/ligament, and drains into the coronary sinus. Ventricular lead placement can be challenging but can be facilitated by shaping the stylet with a large J curve (*Figure 5*). It is useful to search for an innominate vein which is sometimes present (but may be small) and can facilitate implantation from the usual route. Right-

sided implant may be necessary, but a right superior vena cava may be absent in a minority of cases. Right sided venography is advisable to check for presence of a right-sided superior vena cava, before attempting to switch sides, should a PLSVC be identified.

Right ventricular lead placement

The ventricular lead is usually placed before the atrial lead (unless AAI pacing is considered) in order to provide backup pacing and to avoid dislodgment. Anatomic sites for right ventricular pacing are shown in *Figure 6*. According to the 2013 EHRA survey,⁶ half of the centres declared the right ventricular apex (RVA) as their preferred lead position, followed by the interventricular septum and the out-flow tract in 47% and 3% of centres, respectively. A manually curved stylet is often used to cross the tricuspid valve (it is also possible to prolapse the lead off the right atrial wall into the ventricle by manipulating the stylet). Inadvertent cannulation of the coronary sinus or its branches is suggested by 'tracking' of the lead and absence of ventricular premature beats, and can be confirmed in the left anterior oblique (LAO) view.

Right ventricular apex

Leads have traditionally been placed at the RVA due to ease of positioning and presence of trabeculae for anchoring passive leads. Concern has arisen, however, regarding long-term deleterious effects of RVA pacing on left ventricular function, heart failure and death.^{82,83} In addition, it has been shown that perforation is independently associated with an RVA position for active-fixation leads (OR 3.37, 95% CI 1.17–9.67, $P = 0.024$).⁸⁴

As a general rule, with extendible helix leads, fluoroscopic markers should be used for confirming deployment (and not number of turns). Over-rotation may result in lead destabilization, perforation,

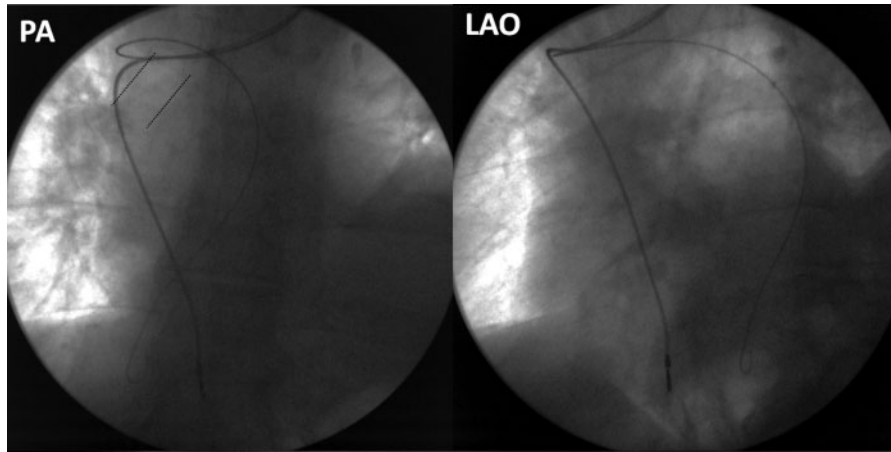


Figure 4 Unintentional cannulation of the azygous vein by the J-wire, with the pacing lead in the superior vena cava/right atrium for comparison. Note the course of the J-wire above the right main bronchus shown by the dotted lines in the postero-anterior (PA) view, which plunges posteriorly in the left anterior oblique (LAO) view.

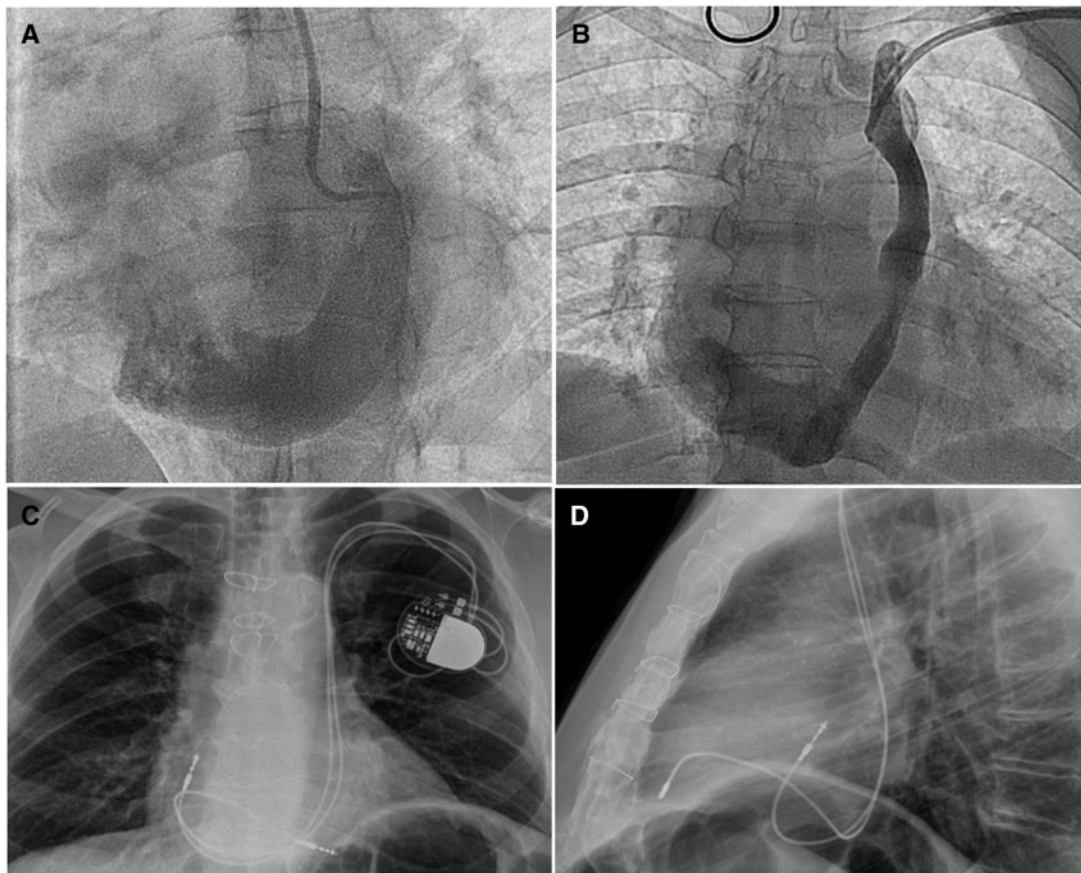


Figure 5 Persistent left superior vena cava. (A) Single left superior vena cava (absent right superior vena cava) draining into a severely dilated coronary sinus. (B) Persistent left superior vena cava in a patient with a coexistent right vena cava (without a bridging innominate vein) and smaller size of the coronary sinus. (C) Same patient as A with a dual chamber pacemaker (PA view). Note the lead course leftward of the spine, and the alpha loop of the right ventricular lead. (D) Same patient as A (left lateral view). Note the posterior course of both leads within the coronary sinus.

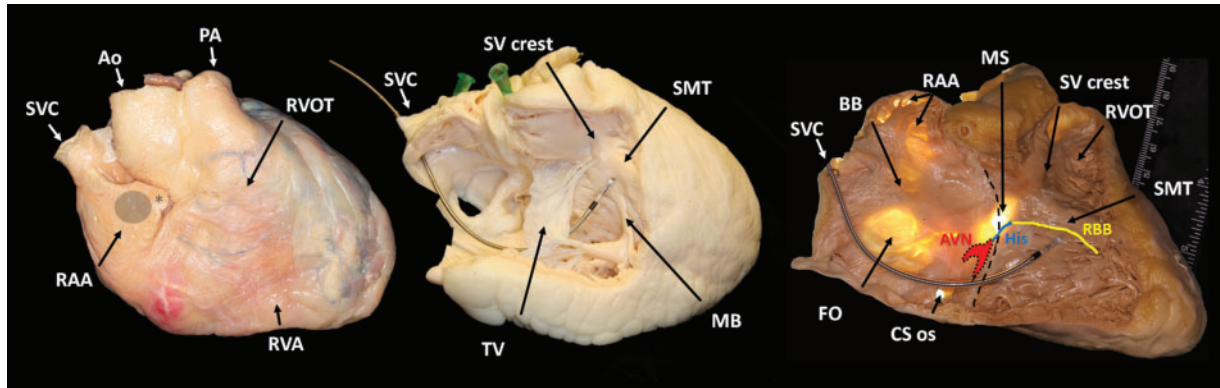


Figure 6 Anatomy of the heart chambers relevant for pacing. (Left) Right anterior oblique view ($\sim 20^\circ$) of the heart. Note proximity of the tip (*) of the right atrial appendage (RAA) to the aortic root (Ao) and the right ventricle. The target site for right atrial lead implantation is shaded (grey circle). (Middle) Right anterior oblique view ($\sim 20^\circ$) of the heart after dissection of the anterior wall of the right heart chambers. The pacing lead is positioned on the mid-septum against the septo-marginal trabeculation (SMT) below the supraventricular crest (SVcrest), which forms the inferior border of the right ventricular outflow tract (RVOT). A noticeable «jump» can be seen as the lead is pulled back from the RVOT over these structures. (Right) Right anterior oblique view ($\sim 30^\circ$) of the dissected transilluminated heart. Note how thin the right atrial appendage (RAA) wall is between pectinate muscles. The tricuspid valve leaflets have been excised to expose the membranous septum (MS), and their hinge points are represented by the dotted line. Approximate location of the atrioventricular node (AVN) and course of the His bundle and right bundle branch (RBB) are shown. Other abbreviations: BB, Bachmann's bundle region; CS, coronary sinus; FO, fossa ovalis; PA, pulmonary artery; RVA, right ventricular apex; SVC, superior vena cava; TV, anterior leaflet of tricuspid valve. Images courtesy of Maxim Didenko, MD, PhD.

Table 5 Practical tips for safe and effective lead implantation

Do	Don't
Manipulate lead/stylet carefully	Manipulate stylet with bloody gloves (\Rightarrow clogging of lead lumen)
Withdraw the stylet by 1–2 cm when advancing the lead up against the ventricular free wall ^a	Apply excessive wall contact with a fully deployed stylet in the lead ^a
Check lead position in the RAO 30° and LAO 40 – 60° views	Over-rotate when fixating (will result in rotation of the entire lead body, with reduced stability and increased risk of perforation) ^b
Deploy the screw while maintaining the exposed part of the lead straight to avoid torque buildup and sudden extension of the helix ^b	Base helix deployment on the number of rotations (variable with lead course) ^b
Check the fluoroscopic markers for helix extension ^b	Let the pinch-on tool spin back after fixation ^b (will partially unscrew helix)
Check for current of injury ^b	Pull on the lead for verifying stability
Test for extracardiac stimulation ^a	
Verify stability of the lead by <i>pushing</i> the lead with the stylet retracted by 5–6 cm	
Leave adequate slack (and check with deep inspiration)	
Check sensing amplitude after having adjusted lead slack	
Clean the connector pin before inserting into the generator	

^aAt the right ventricular apex.

^bWith an active-fixation lead.

LAO, left anterior oblique; RAO, right anterior oblique.

or damage to the lead. This writing group recommends a number of practical precautions to avoid complications when implanting any type of lead (see Table 5).

The lead may be positioned slightly proximal to the apex so as to point in a slightly inferior orientation. The right anterior oblique (RAO) 30° view is useful to expose the long axis of the heart and better outline the apex (see Figure 7). The LAO 40 – 60° view should also

be checked to ensure that the lead is not inadvertently placed in a coronary sinus tributary or in the left ventricle via a septal defect (or arterial puncture), as this can be missed in the postero-anterior view.^{85,86}

Lead stability should be checked by withdrawing the stylet to the level of the inlet and buckling the lead by pushing it. Sufficient slack should be left to form a 'heel'. Temporary pacing at maximum output

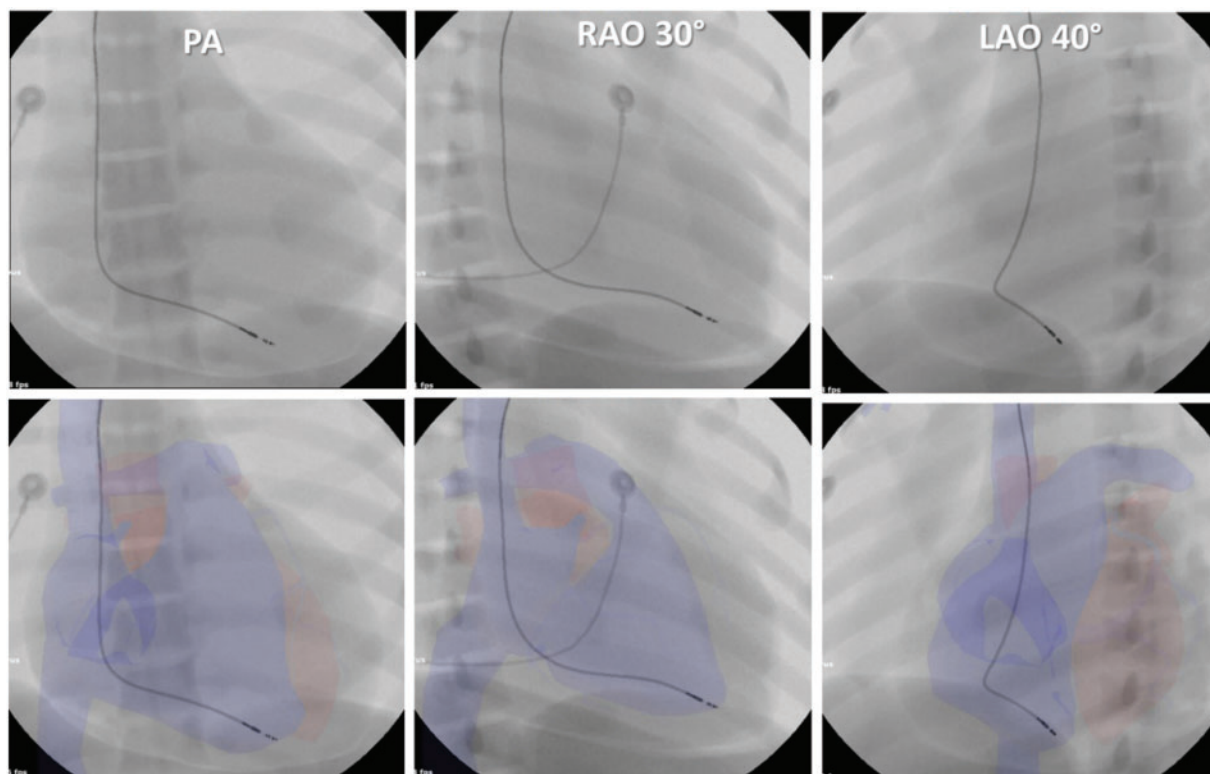


Figure 7 Lead position in the right ventricular apex. Note how the apical position is more apparent in the right anterior oblique (RAO) 30° view than in the postero-anterior (PA) view. The left anterior oblique (LAO) view allows to rule out placement of the lead in the left ventricle via a septal defect or in a tributary of the coronary sinus (e.g. in a posterior vein). Images modified from a virtual reality simulator used for training device implantation, with anatomy reconstructed from patient CT scans.

should be performed while palpating or observing under fluoroscopy the left hemi-diaphragm to rule out phrenic capture. Implantation technique is shown in [Supplementary material online, Video S8](#).

Right ventricular septum

The right ventricular septum (RVS) has been advocated as a more physiological alternative to the RVA to reduce adverse effects of pacing-induced dyssynchrony, with equivocal results.^{82,83} Right ventricular systolic function⁸⁷ and tricuspid regurgitation^{87,88} are also similar to apical pacing. Nevertheless, an advantage is that perforation may be avoided. Electrical parameters are comparable to apical pacing.^{89,90}

A caveat is that many reports have shown that leads intended for the RVS are often positioned on the anterior free wall or antero-septal groove (which forms a natural recess into which the lead wedges).^{91–95} This site may possibly result in left ventricular dysfunction,^{92,93} perforation,⁸⁹ and in rare instances in myocardial infarction, due to the lead being screwed into the left anterior descending artery.^{96–98} It is therefore important to target a true septal position.

Studies which have validated final lead position by computed tomography (CT) or echocardiography have demonstrated that the LAO view alone is insufficient to confirm septal pacing and that an RAO view to visualize the long axis of the heart is also necessary.^{91,94,95} Likewise, the angle of orientation of the lead in the LAO

view is not indicative of a septal location,^{95,99} as it may simply be modified by adjusting lead slack.¹⁰⁰ Furthermore, the LAO 40° may not adequately visualize the heart in its short axis, which is often better represented by the LAO 60° view.¹⁰¹

A fluoroscopic landmark which can be used for positioning septal leads is shown in [Figure 8](#).⁹¹

Ventriculography in the RAO 20–30° view can accurately depict the contour of the right ventricle in its long axis for precise targeting of the RVS.⁹⁹ Although this may not be practical to perform on a routine basis, it may be useful in patients with dilated or hypertrophied ventricles, which can alter the cardiac silhouette. One should also evaluate lead tip movement, which is more ample with fixation to the free wall compared to the RVS.

A number of electrocardiographic (ECG) criteria for confirming lead position have been proposed, but are limited by improper validation of the pacing site,^{102,103} or lack of comparison to antero-septal/ anterior free wall pacing.¹⁰⁴ All studies which have used echocardiography,¹⁰⁵ CT scans,^{94,95} or electro-anatomical mapping¹⁰⁶ for validating pacing sites have shown that ECG criteria are unreliable indicators of RVS pacing.

The lead may slide on the RVS using a two-dimensional curved stylet. In order to facilitate positioning the lead, a posterior distal bend can be made (see [Figure 9](#)) to shape a three-dimensional (3D) stylet as initially described by Mond *et al.*^{91,107}

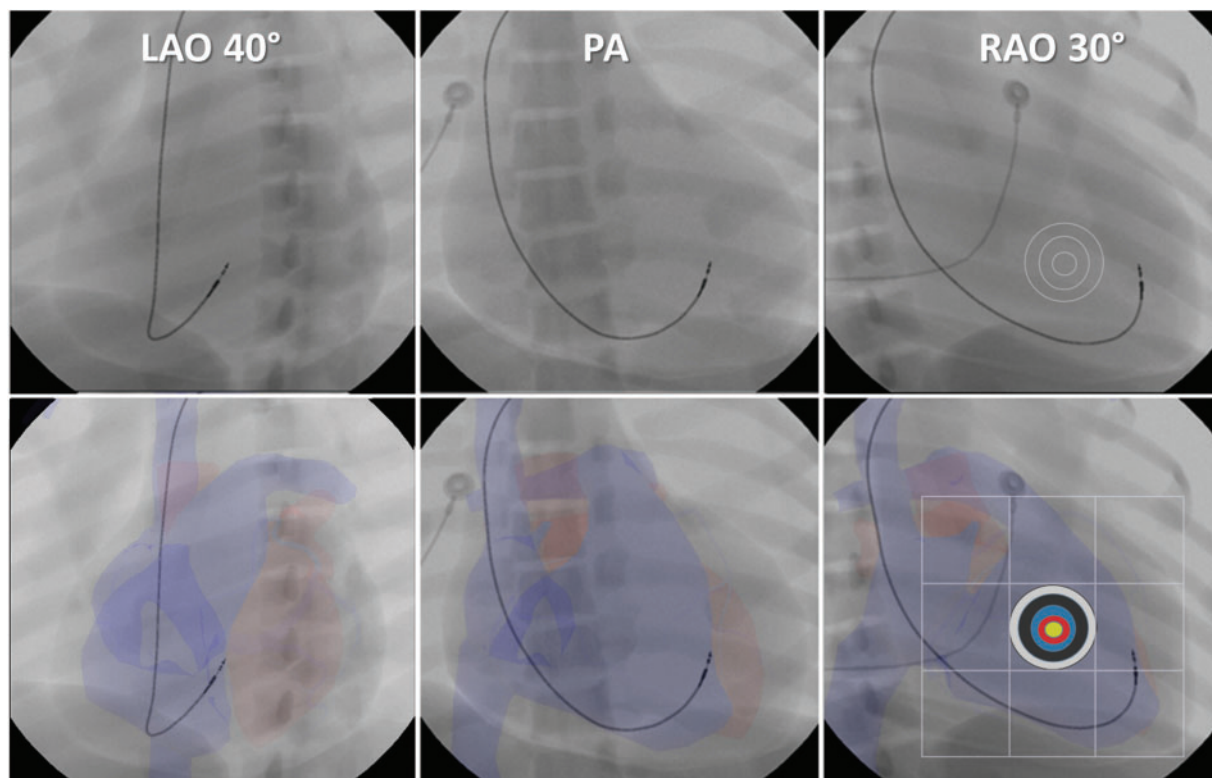


Figure 8 Fluoroscopic landmarks for right ventricular mid-septal lead positioning. The lead is implanted in the antero-septal groove and masquerades as a septal position in the left anterior oblique (LAO) 40–60° and postero-anterior (PA) views. The Right anterior oblique (RAO) 20–30° view shows that the lead is in fact anterior. A 3 × 3 grid can be drawn from the lateral border of the spinal column to the apex in the RAO 20–30° view, targeting the middle square.⁹¹ Dilatation or hypertrophy of the left ventricle may however modify the cardiac silhouette and the landmark. Images modified from Burri *et al.*⁹¹

Positioning may either be done using the ‘pullback’ technique from the pulmonary artery (see [Supplementary material online, Video S9](#)) or directly on the RVS. By combining the 3D stylet and the fluoroscopic landmarks described above in the RAO 30° and LAO 40–60° views, around 95% of the leads can be correctly placed on the RVS.^{91,94} The target area is the septomarginal trabeculation/moderator band (see [Figure 6](#)), which form a natural buttress to stabilize the lead and also harbours the right bundle branch¹⁰⁸ and may also help preserve electrical synchrony.

Only active fixation leads should be used for RVS pacing as this allows positioning in smooth-walled regions. If the lead is not stable, it will usually drop with stylet withdrawal. It is important to adjust lead slack to avoid rocking of the lead tip, which may result in dislodgement (as will too little slack, see [Supplementary material online, Video S9](#)).

Right ventricular outflow tract pacing

The same stylet shape and fluoroscopic views (RAO/LAO) can be used for implanting leads on the right ventricular outflow tract (RVOT) septum as for the RVS. This may however be more challenging, with heterogeneous lead positions,^{109–111} due to the smaller target area of this funnel-shaped structure. Furthermore, the RVOT septum is free-standing, except for its inferior part, i.e. without direct

contact with the interventricular septum,¹¹² and it is thin-walled, tapering from 3–5 mm down to 1–2 mm in its subvalvular segment,¹⁰⁸ raising concern for perforation. There is little evidence that this pacing site is beneficial, although long-term lead performance has been shown to be satisfactory.^{113,114}

Right atrial lead placement

Right atrial leads with dual-chamber devices have been consistently associated with a 1.5–2× increased risk of complications compared to single chamber VVI-systems.^{17,115–120} The main issues are lead dislodgement and perforation.¹²¹ Unless the patient has a VDD system (and does not require atrial pacing), an atrial lead is necessary to maintain atrioventricular synchrony and to confirm atrial arrhythmias. An atrial lead also greatly facilitates follow-up of arrhythmic episodes with ICDs, and tended to reduce inappropriate shocks in a meta-analysis of six trials randomizing single- vs. dual-chamber ICDs (OR 1.46, 95% CI 0.97–2.19; $P=0.07$), without, however, impacting mortality.¹²²

Right atrial appendage

The right atrial appendage (RAA) comprises the entire trabeculated anterolateral triangular part of the right atrium. It is demarcated posteriorly by the crista terminalis, which separates it from the smooth-

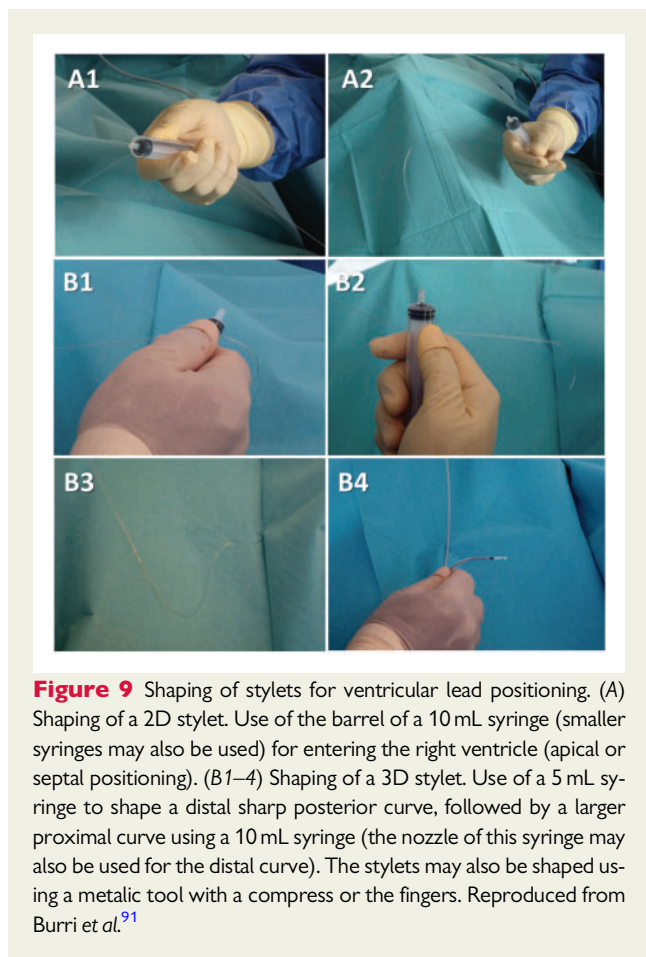


Figure 9 Shaping of stylets for ventricular lead positioning. (A) Shaping of a 2D stylet. Use of the barrel of a 10 mL syringe (smaller syringes may also be used) for entering the right ventricle (apical or septal positioning). (B1–4) Shaping of a 3D stylet. Use of a 5 mL syringe to shape a distal sharp posterior curve, followed by a larger proximal curve using a 10 mL syringe (the nozzle of this syringe may also be used for the distal curve). The stylets may also be shaped using a metallic tool with a compress or the fingers. Reproduced from Burri et al.⁹¹

walled vestibule. Wall thickness is 1–2 mm, with the lateral appendage being particularly thin (see Figure 6); histology shows one or few myocytes thickness between pectinate muscles with some areas being devoid of myocardium.^{123,124} One should therefore avoid placing leads on the lateral wall of the RAA and right atrium to avoid perforation, which may result in tamponade, or in rare instances, right-sided pneumothorax and pneumopericardium.^{125–128} The tip of the RAA points leftwards to lie over the aortic root,¹²⁹ which can result in life-threatening laceration of the aorta by active-fixation leads.^{124,130–133} It is therefore probably advisable to place the right atrial lead in the anterior RAA (see Figure 6).

Patients may complain of parasternal pain during implantation, which may indicate perforation despite normal electrical parameters (and is confirmed if the pain disappears after repositioning the lead). Passive J-shaped leads have been shown to have a lower risk of pericardial complications than active leads,^{121,134} but may be slightly more prone to dislodgment.^{134–136} Active J-shaped leads do not confer any major advantage compared to straight leads.^{137,138}

The medial RAA is also in proximity to the RVOT,¹²⁴ which can result in far-field R-wave (FFRW) oversensing. This can lead to inappropriate mode switching in >20% of patients,¹³⁹ to proarrhythmia with atrial antitachycardia pacing,¹⁴⁰ or issues with ICD rhythm discrimination algorithms. FFRW amplitude should therefore be carefully assessed at implantation (ideally before deploying the helix as it is not

affected by fixation) and should be <20% compared to the near-field atrial electrogram. This is best accomplished by direct visualization of the intracardiac electrogram, rather than relying solely on a digital reading of the P-wave amplitude. FFRW amplitude can be reduced by placing the lead in the anterior RAA (pointing towards the operator in a postero-anterior view—see [Supplementary material online, Video S10](#)). It is useful to check lead position in the RAO/LAO views, as the ‘windscreen wiper’ movement may be more visible than in the postero-anterior projection. After fixating the lead, stability should be verified by withdrawing the stylet to the superior vena cava and pushing the lead. Sufficient slack should be left to prevent straightening of the lead, as this may result in suboptimal electrical parameters. It should be borne in mind that the amount of lead slack can significantly change near- and far-field sensing amplitude due to changes in atrial dipole orientation with respect to the activation vector (both in the frontal and horizontal planes).

Alternative pacing sites

In an attempt to reduce AF, alternative pacing sites have been studied. These include Bachmann’s bundle, the coronary sinus ostium area, and even dual site atrial pacing. Meta-analyses have failed to show any advantage of progression to persistent/permanent AF or lead-related complications compared to RAA pacing.^{141,142} The interatrial septum may avoid perforation of the free wall, but proximity to the aortic root with risk of perforation should be borne in mind.¹³¹ Due to these considerations and the added complexity of lead placement, this writing group does not recommend atrial septal pacing as a first-line approach. It may however be useful as an option in case of issues with RAA lead placement (e.g. scarring after cannulation for cardiac surgery).

Electrical testing

Acute capture thresholds should be ≤ 1.5 V@0.5 ms, with sensing amplitudes ≥ 1.5 mV for the atrium and ≥ 4 mV for the ventricle, and lead impedances should be within normal specified limits (usually 400–1200 Ohms). It is important to not simply record measurements, but to observe waveforms (e.g. presence of FFRW on atrial leads, as mentioned above). A negative electrogram can result from reversal of the crocodile clips on the lead¹⁴³ (with elevated capture thresholds) or may indicate lead perforation.¹⁴⁴ With active-fixation leads it is important to confirm presence of current of injury (COI) (see Figure 10).

Some degree of ST elevation on the intracardiac electrogram can be encountered even before helix deployment, simply due to contact with the myocardium. To indicate adequate fixation, the elevation should increase compared to baseline and be clearly visible.^{145–148} Capture thresholds can be high immediately after fixation with a COI, but usually decrease over the following minutes (making it worthwhile to recheck thresholds rather than immediately repositioning the lead). Sensing may also be affected by COI and should be rechecked. The significance of slew rate for adequate lead fixation is uncertain.

Electrical testing is usually straightforward for ventricular leads but may be challenging for atrial leads (see practical tips in the [Supplementary material online, Appendix](#)).

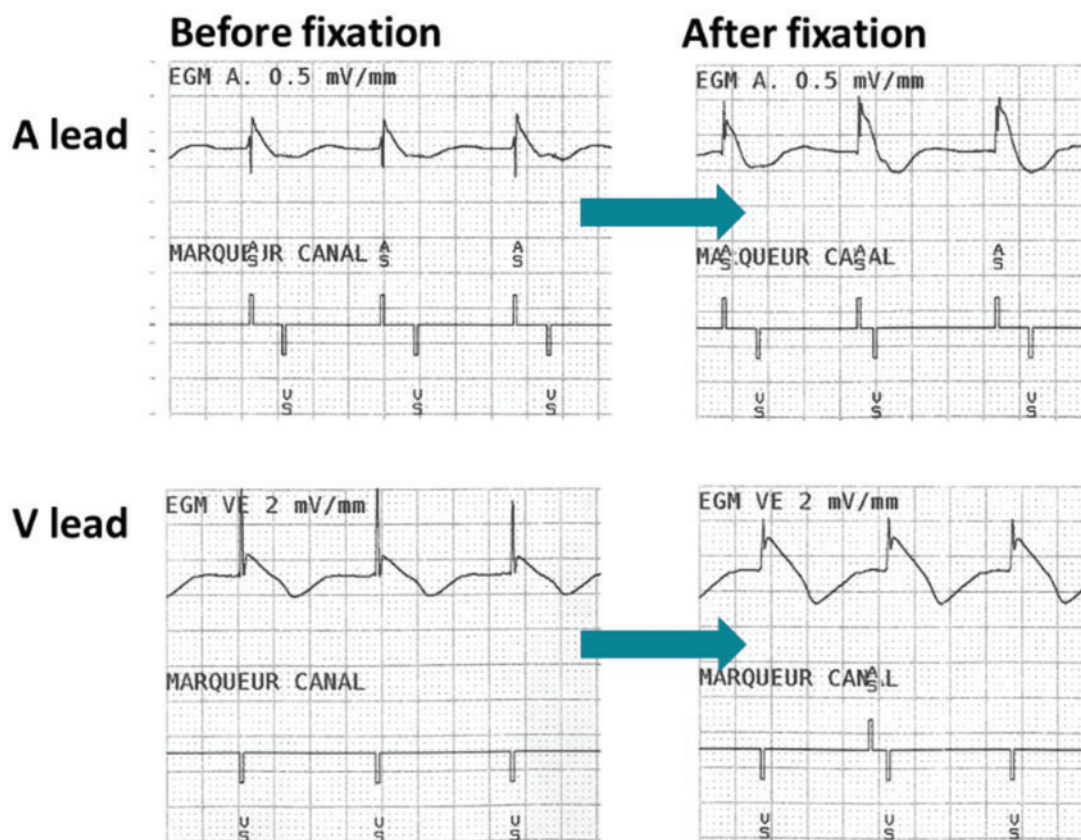


Figure 10 Recordings from the pacing system analyser at implantation. Increase in current of injury before (left) and after (right) helix deployment. *Top:* atrial (A) lead (note absence of a far-field R-wave). *Bottom:* Ventricular (V) lead.

Lead and generator fixation

Haemostatic sutures using resorbable braided sutures around lead insertion sites are useful to control bleeding. However, care should be taken not to tie directly to the lead body as this may damage the insulation (see [Supplementary material online, Video S11](#)). The suture sleeve should be pushed up to the puncture site and non-absorbable braided suture used to secure the lead to the muscular plane, coaxial to lead insertion to avoid kinking. It is important that the sutures be made directly to muscle including the fascia and not to subcutaneous fat. In addition to being friable, the subcutaneous plane is mobile and may result in lead dislodgment in obese patients (particularly in women with large breasts which exert a downward pull and shift this plane). It is important to use an anchor knot technique (i.e. first tie a non-slip knot on the muscle and transverse to fibre orientation) under the sleeve and then tie a loop in the groove of the suture sleeve (see [Figure 11](#)). This is the technique which offers most traction resistance¹⁴⁹ and also prevents dislodgement from ‘ratchet’ or ‘reel’ syndrome^{150–152} resulting from loosening of the tie due to tissue shrinkage if the muscle and sleeve are taken together. A second suture may be placed in the same manner or simply around the sleeve to secure it to the lead. Sutures should never be placed directly on the lead body and should not be too tight as this may cause lead damage. Two or more moderately tight ties will secure the lead better

than one very tight tie, with less risk of lead damage. Stability should be checked by gentle traction on the lead.

Due to differences in auto-initialization methods among manufacturers, it is recommended to manually interrogate devices before implantation.¹⁵³ This also allows to establish wireless communication which is useful to check proper lead connection and parameters. The lead pins should be wiped of blood with a dry swab before being connected to avoid future ‘freezing’ in the header.

The pocket may be irrigated with saline to flush out blood clots and debris. Excess lead length should be coiled in the pocket, with care being taken to avoid kinking (which may result in lead damage), and placed under the generator to avoid inadvertent damage when the pocket is reopened. The header should ideally be oriented towards the incision (see [Figure 12](#), left), as this will facilitate access to the leads during generator change. Fixation of the generator in the pocket is optional (including for ICDs).

Pocket and skin closure

The pocket should be closed by separate stitches (2–4 usually suffice) using resorbable braided suture (see [Figure 12](#), right and [Supplementary material online, Video S12](#)). This avoids migration of the generator and the leads, as well as reduces surface wound tension in case of pocket haematoma. There are several ways of closing the

skin. For example, a running stitch using resorbable 3–0 braided suture can close the subcutaneous plane followed by a subcuticular running stitch using 4–0 monofilament absorbable suture. Barbed sutures obviate the need for knots, but have not shown any significant advantage compared to standard sutures,¹⁵⁴ and are more costly. Skin glue has been compared to sutures in two randomized studies

and was found either to have no significant advantage¹⁵⁵ or more early adverse events (9.3% vs. 6.0%; $P = 0.02$).¹⁵⁶ Some operators use staples, but this has not been evaluated against sutures for PM and ICD implantation, and requires that the patient return to have them removed.

Management of perioperative complications

Although CIED implantation has some potentially fatal complications, procedure-related death is exceptionally rare (0–0.1%).^{17,157–159} Perioperative mortality is mainly due to comorbidities (e.g. heart failure). Perioperative complications are listed in *Table 6*.

Electronic health records or registries which capture complications are useful to keep track of these events for benchmarking or audits.

Perforation and pericarditis/tamponade

The incidence of clinically relevant lead perforation is difficult to determine due to variable definitions, but has been reported to range from 0.09% to 1.5%.^{17,84,120,135,160–165} Lead perforation usually manifests itself as an acute (<24 h) or sub-acute (<1 month) complication, but may rarely occur late, and even be diagnosed years after implantation.^{166,167} The consequences of lead perforation may be acute pericarditis, pericardial effusion or tamponade,^{17,84,120,160–162} constrictive pericarditis,¹⁶⁸ pleural effusion, haemothorax,¹⁶⁹ pneumothorax,^{125,127,170} lung perforation,¹⁷¹ abnormal electrical parameters, and diaphragmatic/intercostal stimulation,¹⁷² but it may also occur without clinical manifestations.¹⁷³

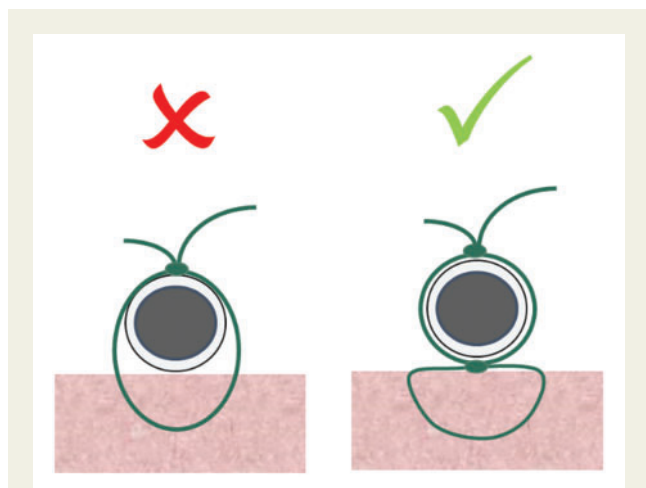


Figure 11 Anchor knot for securing the lead. A non-resorbable braided suture (1, 0 or 1–0) with a large curved needle should be used. *Left:* The lead and muscle should not be taken together for suturing the sleeve to the muscle, as tissue may necrose and shrink, resulting in loosening of the tie. *Right:* An anchor non-slip knot should be placed on the muscle and then sutured to the sleeve. At least one additional suture should be placed, either in the same manner, or simply around the sleeve so as to further secure the lead.

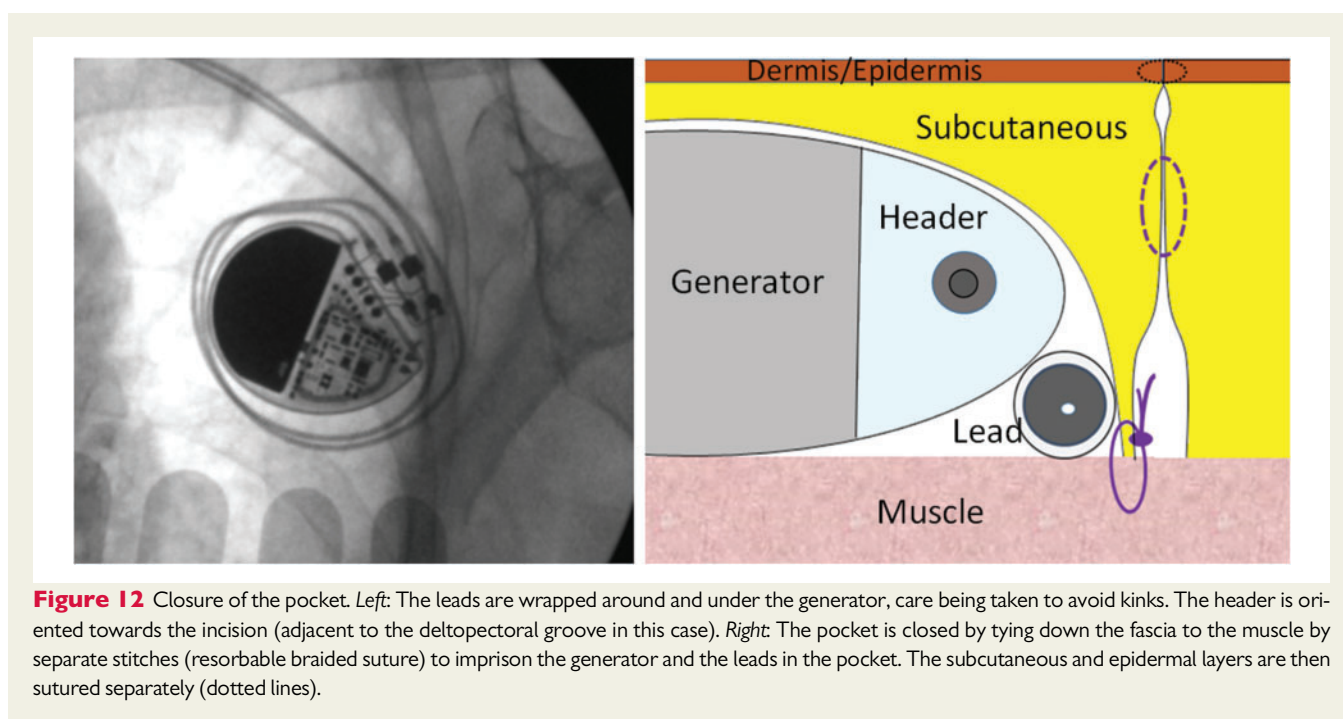


Figure 12 Closure of the pocket. *Left:* The leads are wrapped around and under the generator, care being taken to avoid kinks. The header is oriented towards the incision (adjacent to the deltopectoral groove in this case). *Right:* The pocket is closed by tying down the fascia to the muscle by separate stitches (resorbable braided suture) to imprison the generator and the leads in the pocket. The subcutaneous and epidermal layers are then sutured separately (dotted lines).

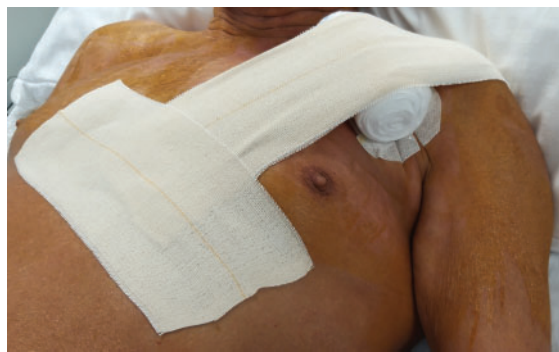

Figure 13 Compressive bandage to avoid haematoma. The roll and tape are placed immediately after the dressing is applied, and left until the following day.

Intra-operative perforation can result in vagal symptoms, chest pain, high capture thresholds, diaphragmatic capture, and inversion of the COI¹⁴⁴ (rarely observed). Tamponade is strongly suggested by haemodynamic compromise (the differential diagnosis being a vagal reaction) and an immobile cardiac silhouette with fluoroscopy (the latter is sometimes present without effusion). Tamponade should be confirmed by echocardiography and treated with emergent pericardiocentesis. In a study including 968 patients who had an echocardiogram performed routinely before and <24 h after CIED implantation, a new mild pericardial effusion (≤ 10 mm in diastole) was found in as many as 8.3% of patients, with moderate (11–20 mm) and large (>20 mm) effusions in 0.4% and 1.5% of patients, respectively.¹⁶² Effusions are asymptomatic in 94% of patients,¹⁶² and therefore go unnoticed in most cases. If pain due to pericardial irritation is present, anti-inflammatory drugs can be administered. Patients with mild or moderate effusions should be monitored closely with continued surveillance after discharge to rule out recurrence/worsening of effusion. In case of haemodynamic compromise or large effusions, pericardiocentesis should be performed,¹⁶² and considered in those with moderate effusions which do not regress quickly, especially if the patient requires antiplatelet drugs and/or anticoagulation. Whether patients who require pericardiocentesis should undergo lead revision is debated. In a retrospective series of 48 patients with definitive perforations, 10 patients had pericardiocentesis for tamponade and were treated conservatively without lead revision, with recurrence of effusion over follow-up in only one patient.¹⁷⁴ However, conservative management of perforation was associated overall with increased complications, mainly tamponade over follow-up in patients who initially had no/mild effusion (most of whom were on antiplatelet drugs and anticoagulants).¹⁷⁴ Lead revision should therefore be carefully evaluated in patients with perforation. Most cases of lead repositioning/replacement are uneventful.¹⁷⁴ However, perforations which are overtly transmural should be treated in centres with cardiac-thoracic surgical standby. The increased risk of infection due to early re-intervention may be mitigated by the use of an antibacterial envelope.¹⁷⁵

Risk factors for lead perforation are shown in Table 7. Although several studies have reported increased incidence of perforation with

Table 6 Perioperative complications with PM and ICD implantation and their incidence

Complication	Incidence
Procedure-related mortality ^{17,157–159}	0–0.1%
30-day mortality	0.6–1.4%
Pneumothorax ^{17,42,43,135,160,178–180}	0.4–2.8%
Clinically relevant perforation ^{17,84,120,135,160–165}	0.1–1.5%
Pericardial effusion ¹⁶²	10.2%
Tamponade ^{84,162}	0.5–1.5%
Pocket haematoma ^{10,11,17,118,119,181}	0.2–16.0%
Infection ⁷	0.6–3.4%
Lead dislodgment ^{3,45,135,160,180,187,188}	1.2–3.3%
Other: arrhythmias ¹²⁰ , pleural effusion, haemothorax, ^{120,169} aortic root perforation, ^{124,130–133} lung perforation, ¹⁷¹ pneumopericardium, ^{128,170} constrictive pericarditis, ^{168,242} air embolism, ^{190,191} myocardial infarction, ^{96–98,120} diaphragmatic ¹³⁵ /intercostal ¹⁷² muscle stimulation, stroke, ¹²⁰ brachial plexus palsy, phrenic nerve palsy, ⁴⁹ acute access vein thrombosis, pulmonary embolus, ¹⁹³ allergy, ^{238–241} damage to tricuspid valve ¹³⁵	<0.5%

active fixation leads,^{163,164,176} a recent large study showed no difference compared to passive leads.¹⁶¹ Nevertheless, passive atrial J-leads^{121,134} or VDD systems (in case atrial pacing is not necessary) can be considered in patients deemed to be at high risk of perforation, although atrial undersensing may be observed in about 10% of patients.¹⁷⁷

Arrhythmias

Audible pulse signals from continuous ECG monitoring during an implant procedure are useful for immediately identifying arrhythmias. Transient traumatic atrioventricular block can occur during right ventricular lead positioning in patients with underlying left bundle branch block. The implanter should anticipate this complication and have cables ready to provide rescue pacing (even prior to lead fixation). Backup transcutaneous pacing should also be available. The block usually resolves within a few minutes, but in some cases may persist for several hours.

Non-sustained ventricular tachycardia is frequent during right ventricular lead placement, and especially during lead manipulation and pullback of the lead from the RVOT. In rare instances, sustained ventricular tachycardia or ventricular fibrillation is induced and may require overdrive pacing or cardioversion/defibrillation. Atrial flutter/fibrillation may also be induced during lead placement.

Preparing pre-positioned defibrillation pads on the patient is strongly recommended to prevent disrupting the sterile field to apply paddles emergently for defibrillation or transcutaneous pacing.

Analysis of arrhythmias is limited by absence of a 12-lead ECG for most standard procedures. Entrainment manoeuvres performed via the pacing system analyser (PSA) can be used to diagnose 1:1 atrioventricular arrhythmias as in the electrophysiology laboratory.

Table 7 Factors affecting risk of lead perforation reported in the literature*Increased risk*

Older age^{84,120}
 Female gender^{84,120,162}
 Body mass index < 20¹⁶³
 Left bundle branch block¹²⁰
 Higher left ventricular ejection fraction¹²⁰
 Heart failure¹²⁰
 Steroid use^{163,165}
 Antiplatelet agents¹⁶²
 Temporary pacing^{163,165}
 Small diameter ICD leads²⁴³
 Active fixation lead^{163,164,176}
 Non-single chamber device (atrial lead)^{120,176}
 Lateral atrial lead¹⁸⁷
 Apical right ventricular lead^{84,187}
 Longer fluoroscopy time¹⁶³

Decreased risk

Right ventricular systolic pressure >35mmHg¹⁶³
 Previous cardiac surgery^{120,162}
 Body mass index > 35¹⁶³
 Atrial fibrillation¹²⁰
 Diabetes mellitus¹²⁰
 Higher implanter procedural volume¹²⁰

Pneumothorax

The incidence of pneumothorax ranges between 0.4% and 2.8%, and is dependent on the venous access chosen for implantation.^{17,42,43,135,160,178–180} Pneumothorax should be suspected if air is aspirated while advancing the needle, although this is not always the case. Fluoroscopy may visualize the pneumothorax if it is large. A routine chest X-ray should be performed within 24 h in all patients. In case of suspected pneumothorax, a chest X-ray should be performed immediately and repeated after several hours or the next day, as the complication may not be initially visible. A CT scan may also be performed if the X-ray is negative but the complication is suspected.¹⁷⁰ In case of a small apical pneumothorax, conservative management may often suffice, with surveillance until resolution of the pneumothorax. In most other instances, a chest tube should be inserted.

Risk factors for the development of a pneumothorax include: age >80 years, female sex, low BMI, chronic obstructive pulmonary disease, and subclavian vein puncture.^{42,43,178} Cephalic vein cutdown or axillary vein puncture⁵⁸ should be preferred to avoid this complication, and the use of a 'Micro-Puncture' needle can minimize damage to the lung.

Pocket haematoma

The incidence of pocket haematoma ranges between 0.2% and 16.0% depending on definition and factors such as anticoagulation

regimen.^{10,11,17,118,119,181} It is associated with an approximately nine-fold increased risk of infection.⁷

Conservative management should be favoured if possible due to 15-fold risk of infection with reintervention.²⁸ However, in cases of wound dehiscence or skin erosion, severe pain, arm swelling, brachial plexus or arterial compromise, a surgical revision should be performed without delay. The procedure should be performed with the strictest precautionary measures by an experienced implanter and use of an antibacterial envelope should be considered. Needle aspiration is contra-indicated as it provides incomplete evacuation and may result in infection by seeding the pocket.

Pocket haematoma should be avoided by optimal perioperative management of anticoagulation and antiplatelet drugs (see Section *Preoperative preparation* and *Table 3*). In addition, good surgical technique with minimal tissue trauma, respecting anatomical planes and with meticulous attention paid to haemostasis should be the norm. Haemostatic resorbable sutures may be placed at venous entry sites (non-resorbable sutures may hamper future lead extraction, if required). Use of a suction drain has been described,¹⁸² but is controversial due to concern for infection. There is little evidence that haemostatic agents are effective.¹⁸³ Compression using sandbags, tapes or vests^{184–186} can be useful to avoid haematoma.

Local and systemic CIED infection

CIED infection is a serious and potentially life-threatening complication. The incidence is reported to be 0.6–3.4%.⁷ Detailed description on diagnosis, treatment and prevention can be found in a recent EHRA consensus document.⁷

Lead dislodgement

Lead dislodgment is reported in 1.2–3.3% of implantations.^{3,45,135,160,180,187,188} Most dislodgments occur before discharge.¹⁸⁷ The incidence is significantly higher for atrial leads than for right ventricular leads.^{45,180,187} There is a trend towards fewer dislodgments with active fixation leads compared to passive leads.¹³⁵ Diagnosis is usually confirmed by the chest X-ray after abnormal electrical testing, but micro-dislodgments may not be apparent. Dislodgement usually requires revision, but may be unnecessary if lead function is not compromised or the lead is not absolutely required and there are no adverse effects, such as arrhythmia or lead chatter. If repositioning is necessary, it should be deferred if possible for a few weeks to minimize pain and risk of infection.⁷

Other complications

Inadvertent arterial puncture should be identified before insertion of the sheath by observing pulsatile flow, bright red blood, or guidewire position. Simple compression is usually sufficient, but a vascular closure device or surgical revision may be necessary if the sheath was introduced.¹⁸⁹

Air embolism can cause haemodynamic compromise and is potentially lethal.^{190,191} It is favoured by snoring or deep breathing and can be avoided by the operator temporarily blocking the sheath with a finger and introducing the lead during a breath-hold/expiration, or by using sheaths with haemostatic valves. Fluoroscopy shows air in the

right ventricle and pulmonary artery. Patients may be asymptomatic or complain of dyspnoea. Patients should be placed in a Trendelenburg position, administered 100% oxygen, and if necessary, the air should be aspirated (e.g. with a pigtail or Judkins right diagnostic catheter).

Pneumopericardium may occur as a consequence of atrial lead perforation with right-sided pneumothorax.¹⁹² The diagnosis may be missed on the chest X-ray and may require a CT scan.¹⁷⁰ The issue resolves with drainage of the pneumothorax.

Acute deep vein thrombosis of the access vein may rarely occur within days of implantation,¹⁹³ or after months¹⁹⁴ or years and may in rare instances be associated with pulmonary embolism. The symptoms usually resolve with administration of heparin, followed by oral anticoagulation.

Postoperative management

A chest X-ray (postero-anterior and lateral) should be performed within 24 h in all patients after lead implantation to rule out pneumothorax and document lead position. A 12-lead ECG should be recorded and the device fully checked before discharge.

Patients may be mobilized freely once they have recovered from sedation, and same-day discharge is feasible in selected patients.¹⁹⁵ There is no evidence that limitation of arm movement after implantation avoids dislodgment, as securing by fibrosis requires months. A study randomizing standard care (restriction of abduction and lifting of weights for 6 weeks) vs. shoulder exercises, found significantly less shoulder pain at 1 month in the latter group (33% vs. 5%, $P = 0.02$).¹⁹⁶ For this reason, use of arm slings should be avoided.

The patient should be informed regarding post-operative care, ideally with written instructions. The wound should be properly covered by a dressing for 2–10 days. The patient may shower if he has a waterproof dressing, or otherwise after about a week and clean the upper body with a moist towel in the meantime. Routine wound inspection is not superior to patient-initiated consultation.¹⁹⁷ Patients should be seen in-office at 1–3 months, as delaying to >12 weeks is associated with adverse outcome.¹⁹⁸ Remote monitoring can be useful for early detection of technical issues.¹⁹⁹

Specific considerations for ICD implantation

Implantation of ICDs follows the same steps as for PMs. However, specific aspects deserve consideration. Left-sided implantation should be favoured due to risk of increased DFT and total mortality with right-sided access (although co-morbidities requiring right-sided access, such as haemodialysis or cancer may have confounded outcome).^{200–202} Defibrillation testing is already covered in the 2015 Heart Rhythm Society (HRS)/EHRA/Asia Pacific Heart Rhythm Society (APHRS)/SOLAECE expert consensus statement on optimal ICD programming and testing,²⁰³ without new data which requires modifying these recommendations.

Signal quality

Atrial and ventricular signal quality is of particular importance for rhythm discrimination algorithms to work properly. For example, atrial undersensing during a supra-ventricular tachycardia will fulfil the $V > A$ criterion with misdiagnosis of ventricular tachycardia. Low R-wave amplitude may result in undersensing of ventricular arrhythmias and increases risk of T-wave oversensing due to automatic sensitivity gain levels starting as a percentage of the sensed amplitude. Sensed R-wave amplitude measured by the PSA may not correspond to that of the generator, due to differences in filter settings and regression of COI. It is therefore useful to check signal amplitude detected via the generator before closing the pocket.

The coil of integrated bipolar leads are part of the sensing circuit and records atrial signals in as many as 11% of patients if it lies close to the tricuspid annulus,²⁰⁴ with a risk of double-counting and inappropriate therapy. The ventricular electrogram should therefore be scrutinized for presence of low-amplitude atrial signals when implanting these leads.

As with any procedure involving abandoned leads, care should be taken to avoid chatter with pre-existing leads which can result in spurious arrhythmia detection or inhibition of pacing. This is particularly important with integrated bipolar leads which may be more prone to this phenomenon. In an *in vitro* setting, only metal-metal interaction resulted in chatter, which was prevented by expanded polytetrafluoroethylene coating of the coil.²⁰⁵ Coil coating also reduces fibrous adhesions which facilitate lead extraction.^{206,207}

It is advisable to implant ICD leads and generators from the same manufacturer to preserve labelled magnetic resonance imaging (MRI)-conditionality. In addition, manufacturer-specific signal processing and lead sensing may result in detection issues.²⁰⁸ Further more, elevation of subthreshold impedance values have been reported due to contact interface oxidation between lead pins and set screws that may be of different materials not tested for compatibility.²⁰⁹

Right ventricular lead position

Three studies with a total of 146 patients have randomized ICD lead position between the RVOT and RVA, and found no meaningful differences in DFT, with similar threshold measurements.^{210–212} Two larger studies randomized RVS and RVA ICD lead position, and found no significant differences in outcome between groups. However, in the SPICE study⁹⁰ (which included 299 patients), the RVS group tended to have a higher rate of DFT > 25J (5.0% vs. 2.1%, $P = 0.21$) and a higher rate of ICD lead revisions (6.9% vs. 3.2%, $P = 0.57$). In the SEPTAL study,²¹³ which included 215 patients, the RVS group tended to have a higher incidence of total mortality (7.9% vs. 2.9%, $P = \text{NS}$). The main issue with these studies is that 'mid-septal' lead position was only verified in the LAO view, which is insufficient, as mentioned previously.^{91,94,95} It is therefore likely that many leads were implanted in the anterior free wall and that a true septal position for ICD leads has not been properly validated. For these reasons, it may be preferable to implant ICD leads in the RVA, but alternative sites may be considered in case of suboptimal electrical parameters, or to avoid cardiac perforation associated with thin ICD leads¹²⁰ and certain patient characteristics (see Table 7).

Single-coil vs. dual-coil ICD leads

There has been a shift away from dual-coil ICD leads due to difficult and more risky lead extraction as a result of the proximal coil being fibrosed to the superior vena cava.^{206,214} In a meta-analysis of 16 studies, there was a clinically irrelevant reduction in DFT with dual-coil leads (mean 0.81 J, 95% CI 0.31–1.30 J) and no difference in first shock efficacy.²¹⁵ Nevertheless, dual-coil leads may have a higher shock conversion rate of atrial arrhythmias (44.0% vs. 28.8%, $P = 0.07$ in the SIMPLE study²¹⁶) and offer additional morphology vectors for rhythm discrimination. Also, selected patients with right-sided ICD implants may benefit from dual-coil leads.²⁰⁰

DF-4 vs. DF-1 connector

The DF-4 standard is popular with implanting physicians as it facilitates lead connection. However, it offers fewer options compared to DF-1 leads, such as the requirement to implant a pacing lead when 'downgrading' from an ICD to a PM (e.g. during generator replacement in super-responders to CRT). There is also no possibility (without an adaptor) to implant stand-alone coils (e.g. in the azygos vein) or SQ-arrays in case of a high DFT, or to switch IS-1 connector pins with left ventricular leads during generator replacements in patients with functional recalled leads.^{217,218}

Specific considerations with generator replacement

The REPLACE registry¹¹⁹ provides prospective data in 1750 patients who underwent elective generator replacements. The rate of major adverse events at 6 months' follow-up was 4.0% (generator replacement only) and 15.3% (with addition of a lead). Most complications were lead dislodgment or malfunction, haematoma and infection. Generator replacements are often performed by a junior physician alone, which is questionable given these high rates of adverse events.

The patient's left ventricular ejection fraction should be known, as a generator replacement is an excellent opportunity for device upgrade (to an ICD or CRT^{219–221}) or if downgrade from CRT-D to CRT-P is considered in case of super-response or aging of the patient. Electrical parameters recorded over follow-up should be known, in order to compare them with current findings. In patients with very old leads, it is useful to check the connector standard of the lead (e.g. 5 mm or LV-1) and ensure that the required hardware is available. It is also advisable to determine if any leads are on recall or alert, as abandonment or extraction with replacement vs. continued use needs to be considered before the patient is scheduled for a procedure. Abandoned leads may either be capped or sectioned (care being taken to avoid extrusion of metallic components and also to avoid blood clogging the lumen, which may compromise future extraction). This may be achieved by pulling lead insulation over the sectioned tip or knuckling the extremity, and then fastening a tie. Abandoned leads should be fixated in the pocket to prevent them from migrating under the skin. In patients with a dual-chamber system who have developed permanent AF, alternatives are to either maintain a dual-chamber device to preserve MRI-conditionality, or to abandon the atrial lead.

Patients who are PM-dependent usually have an escape rhythm which emerges after some time spent in VVI 30 b.p.m. Otherwise isoprenaline (1–10 µg/min) will solve this issue in almost all cases and avoid need for temporary pacing.

It is recommended that an X-ray or high-resolution fluoroscopy be done prior to skin incision to evaluate lead damage, with particular attention being paid to the subclavian region, site of fixation sleeves, and along the leads, particularly in specific situations (e.g. conductor externalization of Riata leads). This will also yield information on presence of abandoned leads (which is relevant for MRI-conditionality) and position of the header and leads in the pocket. Independently of the initial incision, access should be performed about 1 cm lateral or superior from the current pocket (and never over the generator) to avoid damaging the leads and to provide a margin between skin closure and the pocket in case of pocket haematoma or superficial infection. The incision may be performed over the initial scar if this is desirable for cosmetic reasons, as long as the scar does not lie over the pocket.

When dissecting fibrotic tissue around the leads, electrocautery may be used in cut mode at low energy settings parallel to the course of the lead without prolonged applications at a fixed position. Improper use of electrocautery may result in thermal damage to the insulation, the risk of which can be reduced using a plasma surgery tool.²²² Electrocautery should be used with extreme caution over the generator (and should not come into contact with the metallic housing) or conductor coil in case of lead insulation failure, as it may induce ventricular arrhythmia.^{223–225}

Leads may be frozen to the header and can be freed using an orthopaedic drill^{226,227} or scalpel²²⁸ (to access the tip from the rear of the header and push out the lead with the wrench), bone cutter²²⁹ or by injecting a solvent (pure ethanol) into the header with a needle.²³⁰ It is also possible to inject lubricant around the pin after removing the setscrew.²²⁹ It is important to avoid this issue by ensuring that lead pins are clean of blood before insertion in the header. The set screw may be frozen, which may require an Allen key to be unscrewed. If the set screw is stripped such that the wrench cannot provide the needed torque, it is sometimes possible to remove the silicone grommet and grasp and turn the set screw from the sides using a small clamp.








In some patients, lead damage may be visualized, and it may be difficult to implant a new lead (e.g. in case of vein obstruction or in a frail patient). It is useful in these instances to have repair kits with silicone sleeves and glue, and tools for lead splicing (e.g. Medtronic 5866–9 M Adaptor, which can be used for salvaging a fractured lead).^{231,232}

Conclusions

Tools and techniques for device implantation have evolved over the years, as has education in this field. Virtual reality simulators are increasingly used to train device implantation in a safe environment^{233–235} and are useful adjuncts for education. This document provides a framework for standardizing PM and ICD implantation. Ultimately, by standardizing the procedure and avoiding poor techniques, the document should serve to improve patient outcome.








Consensus statement tables

Table General considerations

Statement	Class	Evidence
Device indication should be based upon current guidelines and take into account the patient's specific needs.		E
The operation room/catheterization or electrophysiology laboratory must meet aseptic standards for foreign body implants and be ventilated with >15 air changes/h (ideally 20–25 changes/h). ^{13,14}		O
The procedure should be performed or supervised by a proficient physician, with EHRA level 2 or national certification, or equivalent expertise.		E
At least one unscrubbed allied professional or nurse should assist the implanter with the procedure.		E
Anaesthesia standby should be readily available.		E
The operator, or another physician present on site, should be able to perform emergency pericardiocentesis.		E
Exposure to irradiation should be minimized.		E

















E, evidence and expert opinion; M, meta-analysis; O, observational studies; R, randomized trials.

Table Consensus statements for specific operative steps

Consensus statements	Class	Evidence
Perioperative prevention measures performed according to 2019 EHRA consensus document on how to prevent, diagnose, and treat cardiac implantable electronic device infections. ⁷		E
Provide adequate sedation and local anaesthesia, within dosage limits (e.g. lidocaine 4.5 mg/kg). ²²		O
Pocket created at the beginning of the procedure in case of new implants.		E
Subfascial prepectoral (subcutaneous) pocket is preferred over submuscular pocket.		E
Submuscular pocket may be useful in patients with low BMI, as they are at risk for pocket erosion, or for cosmetic reasons.		E
Axillary vein puncture or cephalic venous cutdown are preferred for venous access. ^{29–31,37,40,41}		R, M
Intrathoracic subclavian puncture should not be used as a first-line measure due to the risk of pneumothorax and lead failure. ^{29–31,37,40,41}		R, M





Continued

Table Continued

Consensus statements	Class	Evidence
Intrathoracic subclavian vein puncture may be used in case of failed axillary and cephalic vein access.		E
A fluoroscopically-guided axillary vein puncture aiming for region of the first rib or guided by ultrasound may be performed. ^{41,58–62,64}		O
Caudal 35° tilt to minimize risk of pneumothorax may be used for axillary vein puncture. ⁵⁸		O
A venogram should be performed for venous access in case of failed puncture using other landmarks, or as a first-line approach during training or in patients at high risk of pneumothorax. ^{30,50,54,55}		O
Venoplasty may be considered in case of venous stenosis/obstruction. ^{69,71}		O
Both active- and passive-fixation leads may be used for ventricular pacing, but active leads should be used when targeting the lead on the interventricular septum.		O
Electrical parameters for right ventricular leads at implantation should aim for a capture threshold of <1.5 V/0.5 ms, a sensing amplitude of at least 4 mV, and impedance within normal limits for the lead.		E
The anterior right atrial appendage should be the preferred as a first-line approach for atrial pacing, with alternative pacing sites in case of lead implantation (e.g. poor stability or electrical parameters).		E
A passive J-shaped lead may be used as an alternative to active fixation lead to avoid atrial perforation. ^{121,134}		O
Multiple fluoroscopic views may be used routinely for implanting right atrial leads.		E
Electrical parameters at atrial lead implantation should aim for capture threshold <1.5 V/0.5 ms, >1.5 mV sensing amplitude, far-field R-wave <20% of P-wave amplitude, and impedances within normal limits for the lead.		E
For active-fixation leads, helix extension should be based upon specific fluoroscopic markers, and not the number of rotations.		E
For active-fixation leads, a clear current of injury should be visualized. ^{145–148}		O
Leads should be fixated to the fascia and muscle using an anchor knot with additional ties to secure the sleeve to the lead. ¹⁴⁹		E
The generator may be optionally fixated to the muscular plane.		E
The pocket should be closed to prevent migration of the leads and the generator.		E





E, evidence and expert opinion; M, meta-analysis; O, observational studies; R, randomized trials.

Table Consensus statements for ICD implantation

Consensus statements	Class	Evidence
Left-sided implantation of ICDs should be favoured due to lower defibrillation thresholds (and non-dominance for most patients). ^{200,201}		O
Defibrillation testing is optional and may be reserved for special circumstances. ^{203,244,245}		R, M
Single coil ICD leads should be used in most instances to avoid adhesions of the proximal coil which make extraction more difficult. ^{206,214}		O
Dual-coil ICD leads may be useful in specific situations (e.g. high defibrillation thresholds, right-sided implantations, more options for morphology templates etc.). ^{200,215}		O



E, evidence and expert opinion; M, meta-analysis; O, observational studies; R, randomized trials.

Table Consensus statements for pacemaker and ICD generator replacement

Consensus statements	Class	Evidence
The patient's clinical status and left ventricular ejection fraction should be known before generator replacement, in order to evaluate requirement for upgrade to ICD and/or CRT. ²¹⁹⁻²²¹		E
Lead connector pin standards should be verified routinely before generator change.		E
An X-ray or high-resolution fluoroscopy should be routinely performed prior to generator replacement to check for lead integrity.		E
Electrocautery should be used with extreme caution near the generator or in case of lead insulation failure, as this can induce life-threatening ventricular arrhythmias. ²²³⁻²²⁵		O






E, evidence and expert opinion; M, meta-analysis; O, observational studies; R, randomized trials.

Table Consensus statements for management of complications

Consensus statements	Class	Evidence
Effusions which are large (>20 mm in diastole) or of any size when causing haemodynamic compromise should be treated with pericardiocentesis. ¹⁶²		O
Moderate effusions (11–20 mm in diastole) which do not regress quickly may be treated by pericardiocentesis.		E








Continued

Table Continued

Consensus statements	Class	Evidence
Patients with stable mild effusions (<10 mm in diastole) should be monitored closely with continued surveillance after discharge to rule out recurrence/worsening of effusion. ¹⁶²		O
Lead revision may be indicated in selected patients in case of perforation, especially those requiring antiplatelets and/or anticoagulants, as conservative management is associated with increased complications. ¹⁷⁴		O
Pneumothorax should be drained with a chest tube unless it is small or regresses in a few days.		E
Haematomas should be conservatively treated unless there is wound dehiscence or skin erosion, severe pain, arm swelling or brachial plexus/arterial compromise, when surgical revision should be performed without delay.		E
Needle aspiration should not be performed to evacuate a haematoma.		E

E, evidence and expert opinion; M, meta-analysis; O, observational studies; R, randomized trials

Table Consensus statements for post-operative care

Consensus statements	Class	Evidence
A chest X-ray (postero-anterior and if possible lateral) should be performed in all patients after lead implantation and before discharge to rule out pneumothorax and document lead position.		E
Patients can be mobilized freely after device implantation once they have recovered from sedation.		E
Compression using sandbags, tapes or vests can be useful to avoid haematoma. ¹⁸⁴⁻¹⁸⁶		O
Patients do not need to restrict arm movements after device implantation, as this has not been shown to reduce risk of lead dislodgment and may increase shoulder pain. ¹⁹⁶		O
The wound should be properly covered for 2–10 days, ideally with a waterproof dressing.		E
After discharge, patient-initiated consultation in case of problems may be sufficient in most cases (i.e. instead of routine wound inspection). ¹⁹⁷		O
Patients should be seen in-office within 2–12 weeks. ¹⁹⁸		O

E, evidence and expert opinion; M, meta-analysis; O, observational studies; R, randomized trials.

Supplementary material

Supplementary material is available at *Europace* online.

Acknowledgements

The authors thank the EHRA Scientific Document Committee: Dr Nikolaos Dargès, Dr Serge Boveda, Dr Kevin Vernooy, Prof. Zbigniew Kalarus, Prof. Gulmira Kudaiberdieva, Dr Georges H Mairesse, Prof. Valentina Kutyla, Prof. Thomas Deneke, Prof. Jesper Hastrup Svendsen, Dr Vassil B Traykov, Prof. Arthur Wilde, Prof. Frank R. Heinzel.

Conflict of interest: A.A. is a consultant to Boston Scientific, Backbeat, Biosense Webster, Cairdac, Corvia, Microport CRM, EPD-Philips, Radcliffe Publisher. He received speaker fees from Boston Scientific, Medtronic, and Microport. He participates in clinical trials sponsored by Boston Scientific, Medtronic, EPD-Philips. He has intellectual properties with Boston Scientific, Biosense Webster, and Microport CRM. H.B. has received speaker honoraria from Biotronik and Medtronic and has received institutional fellowship support and research grants from Abbott, Biotronik, Boston Scientific, Medtronic, and Microport. J.-C.D. declares honoraria for lectures, research and travel grants from Abbott, Biotronik, Boston Scientific, Medtronic, Microport. C.J.L. is a consultant to Medtronic and Philips Medical, and has received honoraria from Convatec and Abbott Medical, and research support from Boston Scientific. C.S. declares payment to his institution related to his activity as speaker fees, honoraria, consultancy, advisory board fees, investigator, committee member from Angiodynamics, Medtronic, Spectranetics, Biotronik, Liva Nova (Sorin) and Cook Medical and departmental or institutional research funding from Cook Medical. K.V. is consultant for Medtronic and Abbott. None of the other authors report any conflicts of interest.

References

- Raatikainen MJP, Amar DO, Merkely B, Nielsen JC, Hindricks G, Heidbuchel H *et al.* A decade of information on the use of cardiac implantable electronic devices and interventional electrophysiological procedures in the European Society of Cardiology Countries: 2017 report from the European Heart Rhythm Association. *Europace* 2017;**19**:ii1–90.
- Curtis JP, Luebbert JJ, Wang Y, Rathore SS, Chen J, Heidenreich PA *et al.* Association of physician certification and outcomes among patients receiving an implantable cardioverter-defibrillator. *JAMA* 2009;**301**:1661–70.
- Cheng A, Wang Y, Curtis JP, Varosy PD. Acute lead dislodgements and in-hospital mortality in patients enrolled in the national cardiovascular data registry implantable cardioverter defibrillator registry. *J Am Coll Cardiol* 2010;**56**:1651–6.
- Chui PW, Wang Y, Ranasinghe I, Mitiku TY, Seto AH, Rosman L *et al.* Association of physician specialty with long-term implantable cardioverter-defibrillator complication and reoperations rates. *Circ Cardiovasc Qual Outcomes* 2019;**12**:e005374.
- Merino JL, Arribas F, Botto GL, Huikuri H, Kraemer LI, Linde C *et al.*; on behalf of the 2005-2007 Accreditation Committee; European Heart Rhythm Association; European Society of Cardiology. Core curriculum for the heart rhythm specialist: executive summary. *Europace* 2009;**11**:1381–6.
- Bongiorni MG, Proclemer A, Dobreaanu D, Marinskis G, Pison L, Blomstrom-Lundqvist C *et al.*; conducted by the Scientific Initiative Committee, European Heart Rhythm Association. Preferred tools and techniques for implantation of cardiac electronic devices in Europe: results of the European Heart Rhythm Association survey. *Europace* 2013;**15**:1664–8.
- Blomstrom-Lundqvist C, Traykov V, Erba PA, Burri H, Nielsen JC, Bongiorni MG *et al.* European Heart Rhythm Association (EHRA) international consensus document on how to prevent, diagnose, and treat cardiac implantable electronic device infections-endorsed by the Heart Rhythm Society (HRS), the Asia Pacific Heart Rhythm Society (APHRS), the Latin American Heart Rhythm Society (LAHRS), International Society for Cardiovascular Infectious Diseases (ISCVID) and the European Society of Clinical Microbiology and Infectious Diseases (ESCMID) in collaboration with the European Association for Cardio-Thoracic Surgery (EACTS). *Europace* 2020;**22**:515–49.
- Essebag V, Verma A, Healey JS, Krahn AD, Kalfon E, Coutu B *et al.* Clinically significant pocket hematoma increases long-term risk of device infection: BRUISE CONTROL INFECTION Study. *J Am Coll Cardiol* 2016;**67**:1300–8.
- Sticherling C, Marin F, Birnie D, Boriani G, Calkins H, Dan GA *et al.*; ESC Scientific Document Group. Antithrombotic management in patients undergoing electrophysiological procedures: a European Heart Rhythm Association (EHRA) position document endorsed by the ESC Working Group Thrombosis, Heart Rhythm Society (HRS), and Asia Pacific Heart Rhythm Society (APHRS). *Europace* 2015;**17**:1197–214.
- Birnie DH, Healey JS, Wells GA, Verma A, Tang AS, Krahn AD *et al.* Pacemaker or defibrillator surgery without interruption of anticoagulation. *N Engl J Med* 2013;**368**:2084–93.
- Birnie DH, Healey JS, Wells GA, Ayala-Paredes F, Coutu B, Sumner GL *et al.* Continued vs. interrupted direct oral anticoagulants at the time of device surgery, in patients with moderate to high risk of arterial thrombo-embolic events (BRUISE CONTROL-2). *Eur Heart J* 2018;**39**:3973–9.
- Valgimigli M, Bueno H, Byrne RA, Collet JP, Costa F, Jeppsson A *et al.*; ESC Scientific Document Group. 2017 ESC focused update on dual antiplatelet therapy in coronary artery disease developed in collaboration with EACTS: the Task Force for dual antiplatelet therapy in coronary artery disease of the European Society of Cardiology (ESC) and of the European Association for Cardio-Thoracic Surgery (EACTS). *Eur Heart J* 2018;**39**:213–60.
- Sandoe JA, Barlow G, Chambers JB, Gammage M, Guleri A, Howard P *et al.* Guidelines for the diagnosis, prevention and management of implantable cardiac electronic device infection. Report of a joint Working Party project on behalf of the British Society for Antimicrobial Chemotherapy (BSAC, host organization), British Heart Rhythm Society (BHRS), British Cardiovascular Society (BCS), British Heart Valve Society (BHVS) and British Society for Echocardiography (BSE). *J Antimicrob Chemother* 2015;**70**:325–59.
- WHO. Global Guidelines for the Prevention of Surgical Site Infection. WHO Document Production Services, 2016.
- Bischoff P, Kubilay NZ, Allegranzi B, Egger M, Gastmeier P. Effect of laminar airflow ventilation on surgical site infections: a systematic review and meta-analysis. *Lancet Infect Dis* 2017;**17**:553–61.
- Beldi G, Bisch-Knaden S, Banz V, Muhlemann K, Candinas D. Impact of intraoperative behavior on surgical site infections. *Am J Surg* 2009;**198**:157–62.
- Kirkfeldt RE, Johansen JB, Nohr EA, Jorgensen OD, Nielsen JC. Complications after cardiac implantable electronic device implantations: an analysis of a complete, nationwide cohort in Denmark. *Eur Heart J* 2014;**35**:1186–94.
- Nowak B, Tasche K, Barnewold L, Heller G, Schmidt B, Bordignon S *et al.* Association between hospital procedure volume and early complications after pacemaker implantation: results from a large, unselected, contemporary cohort of the German nationwide obligatory external quality assurance programme. *Europace* 2015;**17**:787–93.
- Heidbuchel H, Wittkamp FH, Vano E, Ernst S, Schilling R, Picano E *et al.*; ESC Scientific Document Group. Practical ways to reduce radiation dose for patients and staff during device implantations and electrophysiological procedures. *Europace* 2014;**16**:946–64.
- Picano E, Vano E, Rehani MM, Cuocolo A, Mont L, Bodi V *et al.* The appropriate and justified use of medical radiation in cardiovascular imaging: a position document of the ESC Associations of Cardiovascular Imaging, Percutaneous Cardiovascular Interventions and Electrophysiology. *Eur Heart J* 2014;**35**:665–72.
- Sarkozy A, De Potter T, Heidbuchel H, Ernst S, Kosiuk J, Vano E *et al.*; ESC Scientific Document Group. Occupational radiation exposure in the electrophysiology laboratory with a focus on personnel with reproductive potential and during pregnancy: a European Heart Rhythm Association (EHRA) consensus document endorsed by the Heart Rhythm Society (HRS). *Europace* 2017;**19**:1909–22.
- Tanawuttiwat T, Thisayakorn P, Viles-Gonzalez JF. LAST (local anesthetic systemic toxicity) but not least: systemic lidocaine toxicity during cardiac intervention. *J Invasive Cardiol* 2014;**26**:E13–15.
- Ilov N, Ilov N, Nechepurenko A, Abdulkadyrov A, Paskeev D, Daminina E *et al.* Arguments to apply epinephrine for pocket hematoma reduction. The MAITRE study. *J Atr Fibrillation* 2016;**9**:1391.
- Lokhandwala D, Gupta A, Desai V, Panicker GK, Vora A. A pilot study comparing two sites for incision during pacemaker implantation and their influence on the scar. *Indian Heart J* 2018;**70**:704–8.
- Giudici MC, Meierbachtol CJ, Paul DL, Krupa RK, Vazquez LD, Barold SS. Submammary device implantation in women: a step-by-step approach. *J Cardiovasc Electrophysiol* 2013;**24**:476–9.
- Obeyesekere MN, Kamari S, Youngs N, Alison J. Long-term performance of submammary defibrillator system. *Europace* 2010;**12**:1239–44.

27. Oh JH, Kim CM, Song SY, Uhm JS, Lew DH, Lee DW. Transaxillary subpectoral placement of cardiac implantable electronic devices in young female patients. *Arch Plast Surg* 2017;**44**:34–41.
28. Klug D, Balde M, Pavin D, Hidden-Lucet F, Clementy J, Sadoul N et al. Risk factors related to infections of implanted pacemakers and cardioverter-defibrillators: results of a large prospective study. *Circulation* 2007;**116**:1349–55.
29. Benz AP, Vamos M, Erath JW, Hohnloser SH. Cephalic vs. subclavian lead implantation in cardiac implantable electronic devices: a systematic review and meta-analysis. *Europace* 2019;**21**:121–9.
30. Calkins H, Ramza BM, Brinker J, Atiga W, Donahue K, Nsah E et al. Prospective randomized comparison of the safety and effectiveness of placement of endocardial pacemaker and defibrillator leads using the extrathoracic subclavian vein guided by contrast venography versus the cephalic approach. *Pacing Clin Electrophysiol* 2001;**24**:456–64.
31. Squara F, Tomi J, Scarlatti D, Theodore G, Mocerri P, Ferrari E. Self-taught axillary vein access without venography for pacemaker implantation: prospective randomized comparison with the cephalic vein access. *Europace* 2017;**19**:2001–6.
32. Chan NY, Kwong NP, Cheong AP. Venous access and long-term pacemaker lead failure: comparing contrast-guided axillary vein puncture with subclavian puncture and cephalic cutdown. *Europace* 2017;**19**:1193–7.
33. Jimenez-Diaz J, Higuera-Sobrinho F, Piqueras-Flores J, Perez-Diaz P, Gonzalez-Marin MA. Fluoroscopy-guided axillary vein access vs cephalic vein access in pacemaker and defibrillator implantation: randomized clinical trial of efficacy and safety. *J Cardiovasc Electrophysiol* 2019;**30**:1588–93.
34. Kolettis TM, Lysitsas DN, Apostolidis D, Baltogiannis GG, Sourla E, Michalis LK. Improved 'cut-down' technique for transvenous pacemaker lead implantation. *Europace* 2010;**12**:1282–5.
35. Neri R, Cesario AS, Baragli D, Monti F, Danisi N, Glaciale G et al. Permanent pacing lead insertion through the cephalic vein using an hydrophilic guidewire. *Pacing Clin Electrophysiol* 2003;**26**:2313–4.
36. Hadjis A, Proietti R, Essebag V. Implantation of cardiac resynchronization therapy devices using three leads by cephalic vein dissection approach. *Europace* 2017;**19**:1514–20.
37. Atti V, Turagam MK, Garg J, Koerber S, Angirekula A, Gopinathannair R et al. Subclavian and axillary vein access versus cephalic vein cutdown for cardiac implantable electronic device implantation: a meta-analysis. *JACC Clin Electrophysiol* 2020;**6**:661–71.
38. Lau EW, Liew R, Harris S. An unusual case of the cephalic vein with a supraclavicular course. *Pacing Clin Electrophysiol* 2007;**30**:719–20.
39. Świątoń EB, Steckiewicz R, Grabowski M, Stolarz P. Selected clinical challenges of a supraclavicular cephalic vein in cardiac implantable electronic device implantation. *Folia Morphol (Warsz)* 2016;**75**:376–81.
40. Liu P, Zhou Y-F, Yang P, Gao Y-S, Zhao G-R, Ren S-Y et al. Optimized axillary vein technique versus subclavian vein technique in cardiovascular implantable electronic device implantation: a randomized controlled study. *Chin Med J (Engl)* 2016;**129**:2647–51.
41. Liccardo M, Nocerino P, Gaia S, Ciardiello C. Efficacy of ultrasound-guided axillary/subclavian venous approaches for pacemaker and defibrillator lead implantation: a randomized study. *J Interv Card Electrophysiol* 2018;**51**:153–60.
42. Kotter J, Lolay G, Charnigo R, Leung S, McKibbin C, Sousa M et al. Predictors, morbidity, and costs associated with pneumothorax during electronic cardiac device implantation. *Pacing Clin Electrophysiol* 2016;**39**:985–91.
43. Kirkfeldt RE, Johansen JB, Nohr EA, Moller M, Arnsbo P, Nielsen JC. Pneumothorax in cardiac pacing: a population-based cohort study of 28,860 Danish patients. *Europace* 2012;**14**:1132–8.
44. Birnie DH, Parkash R, Exner DV, Essebag V, Healey JS, Verma A et al. Clinical predictors of fidelis lead failure: report from the Canadian Heart Rhythm Society Device Committee. *Circulation* 2012;**125**:1217–25.
45. Dębski M, Ulman M, Ząbek A, Boczar K, Haberka K, Kuniewicz M et al. Lead-related complications after DDD pacemaker implantation. *Kardiol Pol* 2018;**76**:1224–31.
46. Kim KH, Park KM, Nam GB, Kim DK, Oh M, Choi H et al. Comparison of the axillary venous approach and subclavian venous approach for efficacy of permanent pacemaker implantation. 8-Year follow-up results. *Circ J* 2014;**78**:865–71.
47. Boulé S, Marquié C, Vanesson-Bricout C, Kouakam C, Brigadeau F, Guédon-Moreau L et al. Clopidogrel increases bleeding complications in patients undergoing heart rhythm device procedures. *Pacing Clin Electrophysiol* 2012;**35**:605–11.
48. Chloroyiannis Y, Reul GJ. Iatrogenic left subclavian artery-to-left brachiocephalic vein fistula—successful repair without a sternotomy. *Tex Heart Inst J* 2004;**31**:172–4.
49. Lopez-Gil M, Fontenla A, Julia J, Parra JJ, Arribas F. Phrenic paralysis during cardiac electronic device implantation: incidence, causes and clinical course. *Europace* 2016;**18**:1561–4.
50. Bernstein NE, Aizer A, Chinitz LA. Use of a lateral infraclavicular puncture to obtain proximal venous access with occluded subclavian/axillary venous systems for cardiac rhythm devices. *Pacing Clin Electrophysiol* 2014;**37**:1017–22.
51. Mehrotra S, Rohit MK. Prospective study to develop surface landmarks for blind axillary vein puncture for permanent pacemaker and defibrillator lead implantation and compare it to available contrast venography guided technique. *Indian Heart J* 2015;**67**:136–40.
52. Cheng X, Jiang H. Prospective randomized study of axillary venous access with or without fluoroscopy-guided in cardiovascular implantable electronic device implantation. *Int J Clin Exp Med* 2019;**12**:6128–33.
53. Imnadze G, Awad K, Wolff E, Amberger J, Franz N, Thale J et al. A novel method of axillary venipuncture using the cephalic vein as a sole anatomic landmark. *Can J Cardiol* 2015;**31**:1067–9.
54. Burri H, Sunthorn H, Dorsaz PA, Shah D. Prospective study of axillary vein puncture with or without contrast venography for pacemaker and defibrillator lead implantation. *Pacing Clin Electrophysiol* 2005;**28**:S280–3.
55. Beig JR, Ganai BA, Alai MS, Lone AA, Hafeez I, Dar MI et al. Contrast venography vs. microwire assisted axillary venipuncture for cardiovascular implantable electronic device implantation. *Europace* 2018;**20**:1318–23.
56. Antonelli D, Feldman A, Freedberg NA, Turgeman Y. Axillary vein puncture without contrast venography for pacemaker and defibrillator leads implantation. *Pacing Clin Electrophysiol* 2013;**36**:1107–10.
57. Vurgun VK, Candemir B, Gerege DM, Goksuluk H, Altin AT, Akyurek O et al. Extrathoracic subclavian-axillary vein location and morphological features over the first rib for pacemaker and defibrillator lead implantation. *Pacing Clin Electrophysiol* 2018;**41**:927–32.
58. Yang F, Kulbak G. A new trick to a routine procedure: taking the fear out of the axillary vein stick using the 35° caudal view. *Europace* 2015;**17**:1157–60.
59. Ahmed AS, Gilge JL, Clark BA, Shah A, Bagga S, Padanilam MS et al. Predictors of successful ultrasound-guided lead implantation. *Pacing Clin Electrophysiol* 2020;**43**:217–22.
60. Franco E, Rodriguez Muñoz D, Matía R, Hernandez-Madrid A, Carbonell San Román A, Sánchez I et al. Wireless ultrasound-guided axillary vein cannulation for the implantation of cardiovascular implantable electric devices. *J Cardiovasc Electrophysiol* 2016;**27**:482–7.
61. Jones DG, Stiles MK, Stewart JT, Armstrong GP. Ultrasound-guided venous access for permanent pacemaker leads. *Pacing Clin Electrophysiol* 2006;**29**:852–7.
62. Lin J, Adsit G, Barnett A, Tattersall M, Field ME, Wright J. Feasibility of ultrasound-guided vascular access during cardiac implantable device placement. *J Interv Card Electrophysiol* 2017;**50**:105–9.
63. Seto AH, Jolly A, Salcedo J. Ultrasound-guided venous access for pacemakers and defibrillators. *J Cardiovasc Electrophysiol* 2013;**24**:370–4.
64. Orihashi K, Imai K, Sato K, Hamamoto M, Okada K, Sueda T. Extrathoracic subclavian venipuncture under ultrasound guidance. *Circ J* 2005;**69**:1111–5.
65. Tagliari AP, Kochi AN, Mastella B, Saadi RP, di Leoni Ferrari A, Saadi EK et al. Axillary vein puncture guided by ultrasound vs cephalic vein dissection in pacemaker and defibrillator implant: A multicenter randomized clinical trial. *Heart Rhythm* 2020;**17**:1554–60.
66. Bozyel S, Yalniz A, Aksu T, Guler TE, Genes S. Ultrasound-guided combined pectoral nerve block and axillary venipuncture for the implantation of cardiac implantable electronic devices. *Pacing Clin Electrophysiol* 2019;**42**:1026–31.
67. Abu-El-Hajja B, Bhave PD, Campbell DN, Mazur A, Hodgson-Zingman DM, Cotlar V et al. Venous stenosis after transvenous lead placement: a study of outcomes and risk factors in 212 consecutive patients. *J Am Heart Assoc* 2015;**4**:e001878.
68. Lickfett L, Bitzen A, Arepally A, Nasir K, Wolpert C, Jeong KM et al. Incidence of venous obstruction following insertion of an implantable cardioverter defibrillator: A study of systematic contrast venography on patients presenting for their first elective ICD generator replacement. *Europace* 2004;**6**:25–31.
69. Morani G, Bolzan B, Valsecchi S, Morosato M, Ribichini FL. Chronic venous obstruction during cardiac device revision: incidence, predictors, and efficacy of percutaneous techniques to overcome the stenosis. *Heart Rhythm* 2020;**17**:258–64.
70. Hosoda J, Ishikawa T, Matsushita K, Matsumoto K, Sugano T, Ishigami T et al. Clinical significance of collateral superficial vein across clavicle in patients with cardiovascular implantable electronic device. *Circ J* 2014;**78**:1846–50.
71. Worley SJ, Gohn DC, Pulliam RW, Raifsnider MA, Ebersole BI, Tuzi J. Subclavian venoplasty by the implanting physicians in 373 patients over 11 years. *Heart Rhythm* 2011;**8**:526–33.
72. McCotter CJ, Angle JF, Prudente LA, Mounsey JP, Ferguson JD, DiMarco JP et al. Placement of transvenous pacemaker and ICD leads across total chronic occlusions. *Pacing Clin Electrophysiol* 2005;**28**:921–5.
73. Aleksic I, Kottenberg-Assenmacher E, Kienbaum P, Szabo AK, Sommer SP, Wieneke H et al. The innominate vein as alternative venous access for complicated implantable cardioverter defibrillator revisions. *Pacing Clin Electrophysiol* 2007;**30**:957–60.

74. Marcial JM, Worley SJ. Venous system interventions for device implantation. *Card Electrophysiol Clin* 2018;**10**:163–77.
75. Luthje L, Zabel M, Seegers J, Zenker D, Vollmann D. Acute and long-term feasibility of contralateral transvenous lead placement with subcutaneous, pre-sternal tunnelling in patients with chronically implanted rhythm devices. *Europace* 2011;**13**:1004–8.
76. Elayi CS, Allen CL, Leung S, Lusher S, Morales GX, Wiisanen M et al. Inside-out access: a new method of lead placement for patients with central venous occlusions. *Heart Rhythm* 2011;**8**:851–7.
77. Cheng A, Brinker JA, Reeves RC, Henrikson CA. Novel approach to obtaining vascular access in patients with abandoned endocardial pacemaker and ICD leads. *J Cardiovasc Electrophysiol* 2007;**18**:339–41.
78. Al-Sadawi M, Budzikowski AS. Unusual venous access for device implantation. *Am J Case Rep* 2019;**20**:1482–6.
79. García Guerrero JJ, Fernández de la Concha Castañeda J, Doblado Calatrava M, Redondo Méndez Á, Lázaro Medrano M, Merchán Herrera A. Transfemoral access when superior venous approach is not feasible equals overall success of permanent pacemaker implantation. Ten-year series. *Pacing Clin Electrophysiol* 2017;**40**:638–43.
80. Mathur G, Stables RH, Heaven D, Ingram A, Sutton R. Permanent pacemaker implantation via the femoral vein: an alternative in cases with contraindications to the pectoral approach. *Europace* 2001;**3**:56–9.
81. Biffi M, Boriani G, Frabetti L, Bronzetti G, Branzi A. Left superior vena cava persistence in patients undergoing pacemaker or cardioverter-defibrillator implantation: a 10-year experience. *Chest* 2001;**120**:139–44.
82. Hussain MA, Furuya-Kanamori LUIS, Kaye G, Clark J, Doi SAR. The effect of right ventricular apical and nonapical pacing on the short- and long-term changes in left ventricular ejection fraction: a systematic review and meta-analysis of randomized-controlled trials. *Pacing Clin Electrophysiol* 2015;**38**:1121–36.
83. Shimony A, Eisenberg MJ, Filion KB, Amit G. Beneficial effects of right ventricular non-apical vs. apical pacing: a systematic review and meta-analysis of randomized-controlled trials. *Europace* 2012;**14**:81–91.
84. Cano O, Andres A, Alonso P, Osca J, Sancho-Tello MJ, Olague J. Incidence and predictors of clinically relevant cardiac perforation associated with systematic implantation of active-fixation pacing and defibrillation leads: a single-centre experience with over 3800 implanted leads. *Europace* 2017;**19**:96–102.
85. Burri H, Sekoranja L. A misguided lead. *Eur Heart J* 2015;**36**:280.
86. Wynn GJ, Weston C, Cooper RJ, Somauroo JD. Inadvertent left ventricular pacing through a patent foramen ovale: identification, management and implications for postpacemaker implantation checks. *BMJ Case Rep* 2013;**2013**:bcr2012008312.
87. Saito M, Iannaccone A, Kaye G, Negishi K, Kosmala W, Marwick TH. Effect of right ventricular pacing on right ventricular mechanics and tricuspid regurgitation in patients with high-grade atrioventricular block and sinus rhythm (from the protection of left ventricular function during right ventricular pacing study). *Am J Cardiol* 2015;**116**:1875–82.
88. Schleifer JW, Pislaru SV, Lin G, Powell BD, Espinosa R, Koestler C et al. Effect of ventricular pacing lead position on tricuspid regurgitation: a randomized prospective trial. *Heart Rhythm* 2018;**15**:1009–16.
89. Burri H, Sunthorn H, Dorsaz PA, Viera I, Shah D. Thresholds and complications with right ventricular septal pacing compared to apical pacing. *Pacing Clin Electrophysiol* 2007;**30**:S75–78.
90. Kolb C, Solzbach U, Biermann J, Semmler V, Kloppe A, Klein N et al. Safety of mid-septal electrode placement in implantable cardioverter defibrillator recipients—results of the SPICE (Septal Positioning of ventricular ICD Electrodes) study. *Int J Cardiol* 2014;**174**:713–20.
91. Burri H, Domenichini G, Sunthorn H, Ganiere V, Stettler C. Comparison of tools and techniques for implanting pacemaker leads on the ventricular mid-septum. *Europace* 2012;**14**:847–52.
92. Domenichini G, Sunthorn H, Fleury E, Foulkes H, Stettler C, Burri H. Pacing of the interventricular septum versus the right ventricular apex: a prospective, randomized study. *Eur J Intern Med* 2012;**23**:621–7.
93. Ng AC, Allman C, Vidaic J, Tie H, Hopkins AP, Leung DY. Long-term impact of right ventricular septal versus apical pacing on left ventricular synchrony and function in patients with second- or third-degree heart block. *Am J Cardiol* 2009;**103**:1096–101.
94. Osmancik P, Stros P, Herman D, Curila K, Petr R. The insufficiency of left anterior oblique and the usefulness of right anterior oblique projection for correct localization of a computed tomography-verified right ventricular lead into the midseptum. *Circ Arrhythm Electrophysiol* 2013;**6**:719–25.
95. Pang BJ, Joshi SB, Lui EH, Tacey MA, Ling LH, Alison J et al. Validation of conventional fluoroscopic and ECG criteria for right ventricular pacemaker lead position using cardiac computed tomography. *Pacing Clin Electrophysiol* 2014;**37**:495–504.
96. Majauskienė E, Aucina G, Semenienė P, Jurkuvenas P, Serpytis P. Myocardial infarction caused by active-fixation ventricular pacing lead screwed into the anterior descending coronary artery. *Int Cardiovasc Res J* 2018;**12**:154–6.
97. Nishiyama N, Takatsuki S, Kimura T, Aizawa Y, Fukumoto K, Hagiwara Y et al. Implantation of the right ventricular lead of an implantable cardioverter-defibrillator complicated by apical myocardial infarction. *Circulation* 2012;**126**:1314–5.
98. Pang BJ, Barold SS, Mond HG. Injury to the coronary arteries and related structures by implantation of cardiac implantable electronic devices. *Europace* 2015;**17**:524–9.
99. Shimeno K, Yoshiyama T, Abe Y, Akamatsu K, Kagawa S, Matsushita T et al. The usefulness of right ventriculography to aid anchoring a pacing lead to the right ventricular septum. *Europace* 2018;**20**:1154–60.
100. Mond HG, Feldman A, Kumar S, Rosso R, Hung TT, Pang B. Alternate site right ventricular pacing: defining template scoring. *Pacing Clin Electrophysiol* 2011;**34**:1080–6.
101. Squara F, Scarlatti D, Riccini P, Garret G, Moceri P, Ferrari E. Individualized left anterior oblique projection: a highly reliable patient-tailored fluoroscopy criterion for right ventricular lead positioning. *Circ Arrhythm Electrophysiol* 2018;**11**:e006107.
102. Andrikopoulos G, Tzeis S, Asbach S, Semmler V, Lennerz C, Solzbach U et al.; on Behalf of the SPICE Study Investigators. A stepwise electrocardiographic algorithm for differentiation of mid-septal vs. apical right ventricular lead positioning: the SPICE ECG substudy. *Europace* 2015;**17**:915–20.
103. Matsuo M, Shimeno K, Yoshiyama T, Matsumura Y, Matsumoto R, Abe Y et al. Utility of the combination of simple electrocardiographic parameters for identifying mid-septal pacing. *J Cardiovasc Electrophysiol* 2019;**30**:2433–40.
104. Zajac D, Farkowski MM, Kowalik I, Jankowska A, Firek B, Szved H et al. A novel ECG-based algorithm to determine right ventricular lead placement in permanent pacemaker patients (RVpace study). *J Cardiovasc Electrophysiol* 2019;**30**:2034–40.
105. Mărgulescu AD, Şuran BM, Rîmbaş RC, Dulgheru RE, Silişte C, Vinereanu D. Accuracy of fluoroscopic and electrocardiographic criteria for pacemaker lead implantation by comparison with three-dimensional echocardiography. *J Am Soc Echocardiogr* 2012;**25**:796–803.
106. Burri H, Park C-I, Zimmermann M, Gentil-Baron P, Stettler C, Sunthorn H et al. Utility of the surface electrocardiogram for confirming right ventricular septal pacing: validation using electroanatomical mapping. *Europace* 2011;**13**:82–6.
107. Hillock RJ, Stevenson IH, Mond HG. The right ventricular outflow tract: a comparative study of septal, anterior wall, and free wall pacing. *Pacing Clin Electrophysiol* 2007;**30**:942–7.
108. Ho SY. Anatomic insights for catheter ablation of ventricular tachycardia. *Heart Rhythm* 2009;**6**:S77–80.
109. Sharma G, Salahuddin S, Sanders P, Gupta H, Gulati G, Jagia P et al. Inadequacy of fluoroscopy and electrocardiogram in predicting septal position in RVOT pacing - Validation with cardiac computed tomography. *Indian Heart J* 2016;**68**:174–80.
110. Chen D, Wei H, Tang J, Liu L, Wu S, Lin C et al. A randomized comparison of fluoroscopic techniques for implanting pacemaker lead on the right ventricular outflow tract septum. *Int J Cardiovasc Imaging* 2016;**32**:721–8.
111. Wei H, Tang J, Chen D, Zhang Q, Liang Y, Liu L et al. Electrocardiographic predictors of validated right ventricular outflow tract septal pacing for correct localization of transthoracic echocardiography. *Clin Cardiol* 2018;**41**:354–9.
112. Saremi F, Ho SY, Sanchez-Quintana D. Morphological Assessment of RVOT: CT and CMR Imaging. *JACC Cardiovasc Imaging* 2013;**6**:631–5.
113. Medi C, Mond HG. Right ventricular outflow tract septal pacing: long-term follow-up of ventricular lead performance. *Pacing Clin Electrophysiol* 2009;**32**:172–6.
114. Vlay SC. Right ventricular outflow tract pacing: practical and beneficial. A 9-year experience of 460 consecutive implants. *Pacing Clin Electrophysiol* 2006;**29**:1055–62.
115. Armaganjian LV, Toff WD, Nielsen JC, Andersen HR, Connolly SJ, Ellenbogen KA et al. Are elderly patients at increased risk of complications following pacemaker implantation? A meta-analysis of randomized trials. *Pacing Clin Electrophysiol* 2012;**35**:131–4.
116. Dodson JA, Reynolds MR, Bao HK, Al-Khatib SM, Peterson ED, Kremers MS et al. Developing a risk model for in-hospital adverse events following implantable cardioverter-defibrillator implantation. *J Am Coll Cardiol* 2014;**63**:788–96.
117. Haines DE, Wang Y, Curtis J. Implantable cardioverter-defibrillator registry risk score models for acute procedural complications or death after implantable cardioverter-defibrillator implantation. *Circulation* 2011;**123**:2069–76.
118. Persson R, Earley A, Garlitski AC, Balk EM, Uhlig K. Adverse events following implantable cardioverter defibrillator implantation: a systematic review. *J Interv Card Electrophysiol* 2014;**40**:191–205.
119. Poole JE, Gleva MJ, Mela T, Chung MK, Uslan DZ, Borge R et al.; for the REPLACE Registry Investigators. Complication rates associated with pacemaker

- or implantable cardioverter-defibrillator generator replacements and upgrade procedures: results from the REPLACE registry. *Circulation* 2010;**122**:1553–61.
120. Hsu JC, Varosy PD, Bao H, Dewland TA, Curtis JP, Marcus GM. Cardiac perforation from implantable cardioverter-defibrillator lead placement: insights from the national cardiovascular data registry. *Circ Cardiovasc Qual Outcomes* 2013;**6**:582–90.
 121. Witt CM, Lenz CJ, Shih HH, Ebrille E, Rosenbaum AN, Aung H et al. Right atrial lead fixation type and lead position are associated with significant variation in complications. *J Interv Card Electrophysiol* 2016;**47**:313–9.
 122. Zeitler EP, Sanders GD, Singh K, Greenfield RA, Gillis AM, Wilkoff BL et al. Single vs. dual chamber implantable cardioverter-defibrillators or programming of implantable cardioverter-defibrillators in patients without a bradycardia pacing indication: systematic review and meta-analysis. *Europace* 2018;**20**:1621–9.
 123. Ueda A, McCarthy KP, Sanchez-Quintana D, Ho SY. Right atrial appendage and vestibule: further anatomical insights with implications for invasive electrophysiology. *Europace* 2013;**15**:728–34.
 124. Zoppo F, Rizzo S, Corrado A, Bertaglia E, Buja G, Thiene G et al. Morphology of right atrial appendage for permanent atrial pacing and risk of iatrogenic perforation of the aorta by active fixation lead. *Heart Rhythm* 2015;**12**:744–50.
 125. Dilling-Boer D, Ector H, Willems R, Heibüchel H. Pericardial effusion and right-sided pneumothorax resulting from an atrial active-fixation lead. *Europace* 2003;**5**:419–23.
 126. Morales-Estrella J, Huded C, Bhargava M, Gildea T, Sampaio Rodrigues T, Almeida FA. Right-sided pneumothorax after cardioverter-defibrillator implantation. *Heart Lung Circ* 2019;**28**:e137–8.
 127. Sebastian CC, Wu WC, Shafer M, Choudhary G, Patel PM. Pneumopericardium and pneumothorax after permanent pacemaker implantation. *Pacing Clin Electrophysiol* 2005;**28**:466–8.
 128. Srivathsan K, Byrne RA, Appleton CP, Scott LRP. Pneumopericardium and pneumothorax contralateral to venous access site after permanent pacemaker implantation. *Europace* 2003;**5**:361–3.
 129. Ho SY, Anderson RH, Sanchez-Quintana D. Gross structure of the atriums: more than an anatomic curiosity? *Pacing Clin Electrophysiol* 2002;**25**:342–50.
 130. Di Marco A, Nuñez E, Osorio K, Dallaglio P, Anguera I, Toscano J et al. Aortic perforation by active-fixation atrial pacing lead: an unusual but serious complication. *Tex Heart Inst J* 2014;**41**:327–8.
 131. Kashani A, Mehdirad A, Fredman C, Barold SS. Aortic perforation by active-fixation atrial pacing lead. *Pacing Clin Electrophysiol* 2004;**27**:417–8.
 132. Kaljusto ML, Tønnessen T. Aortic perforation with cardiac tamponade two weeks after pacemaker implantation. *J Thorac Cardiovasc Surg* 2007;**134**:502–3.
 133. Sticco CC, Barrett LO. Delayed cardiac tamponade by iatrogenic aortic perforation with pacemaker implantation. *J Thorac Cardiovasc Surg* 2006;**131**:480–1.
 134. Luria DM, Feinberg MS, Gurevitz OT, Bar-Lev DS, Granit C, Tanami N et al. Randomized comparison of J-shaped atrial leads with and without active fixation mechanism. *Pacing Clin Electrophysiol* 2007;**30**:412–7.
 135. Udo EO, Zuithoff NP, van Hemel NM, de Cock CC, Hendriks T, Doevendans PA et al. Incidence and predictors of short- and long-term complications in pacemaker therapy: the FOLLOWPACE study. *Heart Rhythm* 2012;**9**:728–5.
 136. Zoppo F, Zerbo F, Brandolino G, Bacchiega E, Lupo A, Bertaglia E. Straight screw-in atrial leads “J-post shaped” in right appendage versus J-shaped systems for permanent atrial pacing: a safety comparison. *Pacing Clin Electrophysiol* 2011;**34**:325–30.
 137. Glikson M, Yaacoby E, Feldman S, Bar-Lev DS, Yaroslavtsev S, Granit C et al. Randomized comparison of J-shaped and straight atrial screw-in pacing leads. *Mayo Clin Proc* 2000;**75**:1269–73.
 138. Luria D, Bar-Lev D, Gurevitz O, Granit H, Rotstein Z, Eldar M et al. Long-term performance of screw-in atrial pacing leads: a randomized comparison of J-shaped and straight leads. *Pacing Clin Electrophysiol* 2005;**28**:898–902.
 139. Fung JW, Sperzel J, Yu CM, Chan JY, Gelder RN, Yang MX et al. Multicenter clinical experience with an atrial lead designed to minimize far-field R-wave sensing. *Europace* 2009;**11**:618–24.
 140. Weretka S, Becker R, Hilbel T, Karle C, Osswald BR, Kuebler W et al. Far-field R wave oversensing in a dual chamber arrhythmia management device: predisposing factors and practical implications. *Pacing Clin Electrophysiol* 2001;**24**:1240–6.
 141. Shali S, Su Y, Ge J. Interatrial septal pacing to suppress atrial fibrillation in patients with dual chamber pacemakers: a meta-analysis of randomized, controlled trials. *Int J Cardiol* 2016;**219**:421–7.
 142. Zhang L, Jiang H, Wang W, Bai J, Liang Y, Su Y et al. Interatrial septum versus right atrial appendage pacing for prevention of atrial fibrillation: a meta-analysis of randomized controlled trials. *Herz* 2018;**43**:438–46.
 143. Kafi M, Aslani A, Haghjoo M. Negative current of injury due to inadvertent polarity reversal during active atrial lead implantation. *J Electrocardiol* 2010;**43**:279–80.
 144. van Gelder BM, Bracke FA. Current of injury (COI) pattern recorded from catheter delivered active fixation pacing leads. *Pacing Clin Electrophysiol* 2008;**31**:786–7; author reply 787.
 145. Haghjoo M, Mollazadeh R, Aslani A, Dastmalchi J, Mashreghi-Moghadam H, Heidari-Mokarrar H et al. Prediction of midterm performance of active-fixation leads using current of injury. *Pacing Clin Electrophysiol* 2014;**37**:231–6.
 146. Saxonhouse SJ, Conti JB, Curtis AB. Current of injury predicts adequate active lead fixation in permanent pacemaker/defibrillation leads. *J Am Coll Cardiol* 2005;**45**:412–7.
 147. Shali S, Su Y, Qin S, Ge J. Could persistency of current of injury forecast successful active-fixation pacing lead implantation? *Int J Cardiol* 2018;**258**:121–5.
 148. Yoshiyama T, Shimeno K, Matsuo M, Matsumoto R, Matsumura Y, Abe Y et al. Efficacy of the current of injury in envisaging the dislodgement of leads implanted in the right atrial septum or the right ventricular septum. *Pacing Clin Electrophysiol* 2019;**42**:603–9.
 149. Rezaadeh S, Wang S, Rizkallah J. Evaluation of common suturing techniques to secure implantable cardiac electronic device leads: which strategy best reduces the lead dislodgement risk? *Can J Surg* 2019;**62**:E7.
 150. Vijay SK, Dwivedi SK, Chandra S, Saran RK. Ratchet-traction effect: an under-diagnosed mechanism of pacing lead dislodgement. *Indian Heart J* 2014;**66**:555–6.
 151. Von Bergen NH, Atkins DL, Gingerich JC, Law IH. Ratchet syndrome, another etiology for pacemaker lead dislodgement: a case report. *Heart Rhythm* 2007;**4**:788–9.
 152. Gul EE, Glover B, Baranchuk A. Unusual lead helix damage due to ‘Selective’ Reel syndrome. *Indian Pacing Electrophysiol J* 2017;**17**:18–19.
 153. Lau YM, Lau CP. Asystole during pulse generator change: unexpected failure of pacemaker implant autoinitialization. *Pacing Clin Electrophysiol* 2016;**39**:194–7.
 154. Khodak A, Budzikowski AS. Use of barbed suture for wound closure in electrophysiology device procedures. *J Atr Fibrillation* 2017;**9**:1571.
 155. Watson T, Nayar V, Prasad R, Ladwiniec A, Rafiq I, Price R et al. Cyanoacrylate topical tissue adhesive for closure of permanent pacemaker wounds. *Br J Cardiol* 2014;**21**:1–3.
 156. Spencker S, Coban N, Koch L, Schirdewan A, Mueller D. Comparison of skin adhesive and absorbable intracutaneous suture for the implantation of cardiac rhythm devices. *Europace* 2011;**13**:416–20.
 157. van Rees JB, de Bie MK, Thijssen J, Borleffs CJ, Schali J, van Erven L. Implantation-related complications of implantable cardioverter-defibrillators and cardiac resynchronization therapy devices: a systematic review of randomized clinical trials. *J Am Coll Cardiol* 2011;**58**:995–1000.
 158. Steinbeck G, Andresen D, Seidl K, Brachmann J, Hoffmann E, Wojciechowski D et al. Defibrillator implantation early after myocardial infarction. *N Engl J Med* 2009;**361**:1427–36.
 159. Nowak B, Misselwitz B, Przibille O, Mehta RH. Is mortality a useful parameter for public reporting in pacemaker implantation? Results of an obligatory external quality control programme. *Europace* 2017;**19**:568–72.
 160. Gadler F, Valzania C, Linde C. Current use of implantable electrical devices in Sweden: data from the Swedish pacemaker and implantable cardioverter-defibrillator registry. *Europace* 2015;**17**:69–77.
 161. Migliore F, Zorzi A, Bertaglia E, Leoni L, Siciliano M, De Lazzari M et al. Incidence, management, and prevention of right ventricular perforation by pacemaker and implantable cardioverter defibrillator leads. *Pacing Clin Electrophysiol* 2014;**37**:1602–9.
 162. Ohlow MA, Lauer B, Brunelli M, Geller JC. Incidence and predictors of pericardial effusion after permanent heart rhythm device implantation: prospective evaluation of 968 consecutive patients. *Circ J* 2013;**77**:975–81.
 163. Mahapatra S, Bybee KA, Bunch TJ, Espinosa RE, Sinak LJ, McGoon MD et al. Incidence and predictors of cardiac perforation after permanent pacemaker placement. *Heart Rhythm* 2005;**2**:907–11.
 164. Sterlinski M, Przybylski A, Maciag A, Syska P, Pytkowski M, Lewandowski M et al. Subacute cardiac perforations associated with active fixation leads. *Europace* 2008;**11**:206–12.
 165. Lin YS, Hung SP, Chen PR, Yang CH, Wo HT, Chang PC et al. Risk factors influencing complications of cardiac implantable electronic device implantation: infection, pneumothorax and heart perforation a nationwide population-based cohort study. *Medicine* 2014;**93**:e213.
 166. Sadamatsu K, Enomoto N, Tsuji M, Tashiro H. Progressive atrial lead perforation developed 5 years after pacemaker replacement. *J Cardiol* 2009;**53**:150–3.
 167. Liang JJ, Killu AM, Osborn MJ, Jaffe AS. Pacemaker lead perforation causing hemopericardium eight years after implantation. *Indian Heart J* 2013;**65**:331–3.
 168. Agarwal N, Mojaddi MK, Ahmed M. Constrictive pericarditis from an endocardial pacemaker lead. *BMJ Case Rep* 2017;**2017**:bcr2016218365.
 169. Merla R, Reddy NK, Kunapuli S, Schwarz E, Vitarrelli A, Rosanio S. Late right ventricular perforation and hemothorax after transvenous defibrillator lead implantation. *Am J Med Sci* 2007;**334**:209–11.

170. Aktaa S, Fatania K, Gains C, White H. Chest pain following permanent pacemaker insertion. . . a case of pneumopericardium due to atrial lead perforation. *BMJ Case Rep* 2018;**2018**:bcr2018226318.
171. Selcuk H, Selcuk MT, Maden O, Ozeke O, Celenk MK, Turkvatan A et al. Uncomplicated heart and lung perforation by a displaced ventricular pacemaker lead: a case report. *Pacing Clin Electrophysiol* 2006;**29**:429–30.
172. Erdogan O. Intercostal muscle twitching: an unusual manifestation of extracardiac stimulation related to right ventricular outflow tract pacing. *Can J Cardiol* 2007;**23**:815–6.
173. Pang BJ, Lui EH, Joshi SB, Tacey MA, Alison J, Seneviratne SK et al. Pacing and implantable cardioverter defibrillator lead perforation as assessed by multiplanar reformatted ECG-gated cardiac computed tomography and clinical correlates. *Pacing Clin Electrophysiol* 2014;**37**:537–45.
174. Acha MR, Rafael A, Keaney JJ, Elitzur Y, Danon A, Shauer A et al. The management of cardiac implantable electronic device lead perforations: a multicentre study. *Europace* 2019;**21**:937–43.
175. Tarakji KG, Mittal S, Kennergren C, Corey R, Poole JE, Schloss E et al. Antibacterial envelope to prevent cardiac implantable device infection. *N Engl J Med* 2019;**380**:1895–905.
176. Sivakumaran S, Irwin ME, Gulamhusein SS, Senaratne MP. Postpacemaker implant pericarditis: incidence and outcomes with active-fixation leads. *Pacing Clin Electrophysiol* 2002;**25**:833–7.
177. Shurrab M, Elitzur Y, Healey JS, Gula L, Kaoutskaia A, Israel C et al. VDD vs DDD pacemakers: a meta-analysis. *Can J Cardiol* 2014;**30**:1385–91.
178. Ogunbayo GO, Charnigo R, Darrat Y, Morales G, Kotter J, Olorunfemi O et al. Incidence, predictors, and outcomes associated with pneumothorax during cardiac electronic device implantation: a 16-year review in over 3.7 million patients. *Heart Rhythm* 2017;**14**:1764–70.
179. Haug B, Kjelsberg K, Lappegard KT. Pacemaker implantation in small hospitals: complication rates comparable to larger centres. *Europace* 2011;**13**:1580–6.
180. Ellenbogen KA, Hellkamp AS, Wilkoff BL, Camunäs JL, Love JC, Hadjis TA et al. Complications arising after implantation of DDD pacemakers: the MOST experience. *Am J Cardiol* 2003;**92**:740–1.
181. Masiero S, Connolly SJ, Birnie D, Neuzner J, Hohnloser SH, Vinolas X et al. Wound haematoma following defibrillator implantation: incidence and predictors in the Shockless Implant Evaluation (SIMPLE) trial. *Europace* 2017;**19**:1002–6.
182. Mukherjee SS, Saggú D, Chennapragada S, Yalagudri S, Nair SG. Device implantation for patients on antiplatelets and anticoagulants: use of suction drain. *Indian Heart J* 2018;**70**: S389–93.
183. Reynbakh O, Akhrass P, Souvaliotis N, Pamidimukala CK, Nahar H, Bastawrose J et al. Use of MPH hemostatic powder for electrophysiology device implantation reduces postoperative rates of pocket hematoma and infection. *Curr Med Res Opin* 2018;**34**:1861–7.
184. Turagam MK, Nagarajan DV, Bartus K, Makkar A, Swarup V. Use of a pocket compression device for the prevention and treatment of pocket hematoma after pacemaker and defibrillator implantation (STOP-HEMATOMA-I). *J Interv Card Electrophysiol* 2017;**49**:197–204.
185. Chien C, Chang Y, Wu Y, Lin P, Chiou W, Chi B et al. Effectiveness of a non-taped compression dress in patients receiving cardiac implantable electronic devices. *Acta Cardiol Sin* 2019;**35**:320–4.
186. Kiuchi K, Okajima K, Tanaka N, Yamamoto Y, Sakai N, Kanda G et al. Novel compression tool to prevent hematomas and skin erosions after device implantation. *Circ J* 2015;**79**:1727–32.
187. Ghani A, Delnoy PP, Ramdat Misier AR, Smit JJ, Adiyaman A, Ottervanger JP et al. Incidence of lead dislodgement, malfunction and perforation during the first year following device implantation. *Neth Heart J* 2014;**22**:286–91.
188. Tseng AS, Shipman JN, Lee JZ, Mi L, Amin M, Killu AM et al. Incidence, patterns, and outcomes after transvenous cardiac device lead macrodislodgment: insights from a population-based study. *Heart Rhythm* 2019;**16**:140–7.
189. Molnár L, Szűcs G, Zima E, Szilágyi S, Kutya V, Becker D et al. Successful management and long term outcome of an accidental subclavian artery injury with a 9 french dilator during pacemaker implantation with collagen-based closure device. *J Interv Card Electrophysiol* 2009;**25**:217–8.
190. Sanjeeva NC, Ramachandran P, Morakhia J, Vivek G. Massive transient pulmonary air embolism during transvenous pacemaker implantation: potentially lethal but avoidable complication. *BMJ Case Rep* 2014;**2014**:bcr2014207053.
191. Vijayvergiya R, Mehrotra S. Acute hemodynamic deterioration during permanent pacemaker implantation. Air embolism. *Heart* 2015;**101**:841–1.
192. Srivathsan K, Byrne RA, Appleton CP, Scott LR. Pneumopericardium and pneumothorax contralateral to venous access site after permanent pacemaker implantation. *Europace* 2003;**5**:361–3.
193. Khalameizer V, Polishchuk I, Pancheva N, Jafari J, Scharf S, Reisin L et al. Multiple-vein thrombosis and pulmonary embolism after pacemaker implantation treated by thrombolysis. *Europace* 2004;**6**:453–6.
194. Mandal S, Pande A, Mandal D, Kumar A, Sarkar A, Kahali D et al. Permanent pacemaker-related upper extremity deep vein thrombosis: a series of 20 cases. *Pacing Clin Electrophysiol* 2012;**35**:1194–8.
195. Darda S, Khouri Y, Gorges R, Al Samara M, Jain SK, Daccarett M et al. Feasibility and safety of same-day discharge after implantable cardioverter defibrillator placement for primary prevention. *Pacing Clin Electrophysiol* 2013;**36**:885–91.
196. Daniels JD, Sun S, Zafereo J, Minhajuddin A, Nguyen C, Obel O et al. Preventing shoulder pain after cardiac rhythm management device implantation: a randomized, controlled study. *Pacing Clin Electrophysiol* 2011;**34**:672–8.
197. Deuling JH, Smit MD, Maass AH, Van den Heuvel AF, Nieuwland W, Zijlstra F et al. The value and limitations of a wound inspection clinic after cardiac device implantation. *Eur J Cardiovasc Nurs* 2009;**8**:288–92.
198. Laksman ZW, Krahn AD, Dorian P, Simpson CS, Crystal E, Healey JS et al. Greater mortality risk among patients with delayed follow-up after implantable cardioverter defibrillator procedures. *Can J Cardiol* 2014;**30**:598–605.
199. Varma N, Epstein AE, Schweikert R, Michalski J, Love CJ. Role of Automatic Wireless Remote Monitoring Immediately Following ICD Implant: The Lumos-T Greater Routine Office Device Follow-Up Study (TRUST) Trial. *J Cardiovasc Electrophysiol* 2016;**27**:321–326.
200. Varma N, Efimov I. Right pectoral implantable cardioverter defibrillators: role of the proximal (SVC) coil. *Pacing Clin Electrophysiol* 2008;**31**:1025–35.
201. Varma N, Schaerf R, Kalbfleisch S, Pimentel R, Kroll MW, Oza A. Defibrillation thresholds with right pectoral implantable cardioverter defibrillators and impact of waveform tuning (the Tilt and Tune trial). *Europace* 2017;**19**:1810–17.
202. Gold MR, Shih HT, Herre J, Breiter D, Zhang Y, Schwartz M. Comparison of defibrillation efficacy and survival associated with right versus left pectoral placement for implantable defibrillators. *Am J Cardiol* 2007;**100**:243–6.
203. Wilkoff BL, Fauchier L, Stiles MK, Morillo CA, Al-Khatib SM, Almendral J et al. 2015 HRS/EHRA/APHS/SOLAECE expert consensus statement on optimal implantable cardioverter-defibrillator programming and testing. *Europace* 2016;**18**:159–83.
204. Weretka S, Michaelsen J, Becker R, Karle CA, Voss F, Hilbel T et al. Ventricular oversensing: a study of 101 patients implanted with dual chamber defibrillators and two different lead systems. *Pacing Clin Electrophysiol* 2003;**26**:65–70.
205. Cooper JM, Sauer WH, Garcia FC, Krautkramer MJ, Verdino RJ. Covering sleeves can shield the high-voltage coils from lead chatter in an integrated bipolar ICD lead. *Europace* 2007;**9**:137–42.
206. Segreti L, Di Cori A, Soldati E, Zucchelli G, Viani S, Paperini L et al. Major predictors of fibrous adhesions in transvenous implantable cardioverter-defibrillator lead extraction. *Heart Rhythm* 2014;**11**:2196–201.
207. Hackler JW, Sun Z, Lindsay BD, Wilkoff BL, Niebauer MJ, Tchou PJ et al. Effectiveness of implantable cardioverter-defibrillator lead coil treatments in facilitating ease of extraction. *Heart Rhythm* 2010;**7**:890–7.
208. Seegers J, Zabel M, Lüthje L, Vollmann D. Ventricular oversensing due to manufacturer-related differences in implantable cardioverter-defibrillator signal processing and sensing lead properties. *Europace* 2010;**12**:1460–6.
209. Mourad AR, Kim MH, Kirk MM. A case series of anomalous high pacing lead impedances in normally functioning leads. *Heart Rhythm Case Rep* 2015;**1**:449–52.
210. Reynolds CR, Nikolski V, Sturdivant JL, Leman RB, Cuoco FA, Wharton JM et al. Randomized comparison of defibrillation thresholds from the right ventricular apex and outflow tract. *Heart Rhythm* 2010;**7**:1561–6.
211. Mollerus M, Lipinski M, Munger T. A randomized comparison of defibrillation thresholds in the right ventricular outflow tract versus right ventricular apex. *J Interv Card Electrophysiol* 2008;**22**:221–5.
212. Crossley GH, Boyce K, Roelke M, Evans J, Yousif D, Syed Z et al. A prospective randomized trial of defibrillation thresholds from the right ventricular outflow tract and the right ventricular apex. *Pacing Clin Electrophysiol* 2009;**32**:166–71.
213. Mabo P, Defaye P, Mouton E, Cebon JP, Davy JM, Tassin A et al. A randomized study of defibrillator lead implantations in the right ventricular mid-septum versus the apex: the SEPTAL study. *J Cardiovasc Electrophysiol* 2012;**23**:853–60.
214. Epstein LM, Love CJ, Wilkoff BL, Chung MK, Hackler JW, Bongiorno MG et al. Superior vena cava defibrillator coils make transvenous lead extraction more challenging and riskier. *J Am Coll Cardiol* 2013;**61**:987–9.
215. Kumar P, Baker M, Gehi AK. Comparison of single-coil and dual-coil implantable defibrillators: a meta-analysis. *JACC Clin Electrophysiol* 2017;**3**:12–19.
216. Neuzner J, Hohnloser SH, Kutya V, Glikson M, Dietze T, Mabo P et al. Effectiveness of single- vs dual-coil implantable defibrillator leads: an observational analysis from the SIMPLE study. *J Cardiovasc Electrophysiol* 2019;**30**:1078–85.
217. Zhu DWX, Chu MM, House CM. Management of functional Sprint Fidelis leads at cardiac resynchronization therapy-defibrillator generator replacement: a novel option for preventing inappropriate shocks from lead failure in fragile patients with high risk of sudden death. *Europace* 2017;**19**:2007–14.

218. Biffi M, de Zan G, Massaro G, Angeletti A, Martignani C, Boriani G et al. Is ventricular sensing always right, when it is left? *Clin Cardiol* 2018;**41**:1238–45.
219. Hoijer CJ, Meurling C, Brandt J. Upgrade to biventricular pacing in patients with conventional pacemakers and heart failure: a double-blind, randomized crossover study. *Europace* 2006;**8**:51–5.
220. van Geldorp IE, Vernooij K, Delhaas T, Prins MH, Crijns HJ, Prinzen FW et al. Beneficial effects of biventricular pacing in chronically right ventricular paced patients with mild cardiomyopathy. *Europace* 2010;**12**:223–9.
221. Begg GA, Gierula J, Waldron ZL, Witte KK. 154 Patients receiving standard pacemaker generator replacements frequently have impaired left ventricular function and exercise intolerance, related to the percentage of right ventricular pacing. *Heart* 2011;**97**:A86–6.
222. Kypta A, Blessberger H, Saleh K, Hönig S, Kammler J, Neeser K et al. An electrical plasma surgery tool for device replacement—retrospective evaluation of complications and economic evaluation of costs and resource use. *Pacing Clin Electrophysiol* 2015;**38**:28–34.
223. Cassagneau R, Hanninen M, Yee R. Electrocautery-induced ventricular fibrillation during routine implantable cardioverter-defibrillator generator replacement. *Europace* 2014;**16**:319.
224. Goel AK, Korotkin S, Walsh D, Bess M, Frawley S. Monomorphic ventricular tachycardia caused by electrocautery during pacemaker generator change in a patient with normal left ventricular function. *Pacing Clin Electrophysiol* 2009;**32**:957–8.
225. Lo R, Mitrache A, Quan W, Cohen TJ. Electrocautery-induced ventricular tachycardia and fibrillation during device implantation and explantation. *J Invasive Cardiol* 2007;**19**:12–15.
226. Ramicone J, Labib A, Wiseman M, Mackall J. An approach to salvage a “frozen” pacing lead. *Pacing Clin Electrophysiol* 2000;**23**:1288–9.
227. Mazzetti HA, Chirife R, Tentori MC, Mascheroni O. Frozen leads: a simple solution for an old problem. *Pacing Clin Electrophysiol* 2002;**25**:1087–9.
228. Güldal M, Altin AT, Özdemir AO, Akyürek ÖMER, Karaoğuz R, Oral D. A safe and simple method for management of frozen pacemaker leads. *Pacing Clin Electrophysiol* 2003;**26**:2336–7.
229. Fisher JD, Lapman P, Kim SG, Ferrick KJ, Gross JN, Palma EC et al. Lead stuck (frozen) in header: salvage by bone cutter versus other techniques. *Pacing Clin Electrophysiol* 2004;**27**:1136–43.
230. Erne P, Kobza R, Lehner M, Resnik TJ. Solvent-facilitated lead disconnection for battery replacement in patients with pacemakers or implantable cardioverter defibrillators. *Europace* 2016;**18**:1241–44.
231. Chambers S, Rusanov A, Spotnitz HM, Silver ES, Liberman L. Durability of repaired pacemaker leads in the pediatric population. *J Interv Card Electrophysiol* 2011;**30**:267–71.
232. Mahapatra S, Homoud MK, Wang PJ, Estes NA 3rd, Link MS. Durability of repaired sensing leads equivalent to that of new leads in implantable cardioverter defibrillator patients with sensing abnormalities. *Pacing Clin Electrophysiol* 2003;**26**:2225–9.
233. Mascheroni J, Mont L, Stockburger M, Patwala A, Retzlaff H, Gallagher AG. A validation study of intraoperative performance metrics for training novice cardiac resynchronization therapy implanters. *Int J Cardiol* 2020;**307**:48–54.
234. Mascheroni J, Mont L, Stockburger M, Patwala A, Retzlaff H, Gallagher AG et al. International expert consensus on a scientific approach to training novice cardiac resynchronization therapy implanters using performance quality metrics. *Int J Cardiol* 2019;**289**:63–9.
235. Morgan JM, Burri H, Binner L, Mansour H, Retzlaff H, Roca M et al. The imperative for metrics in training. *Eur Heart J* 2011;**32**:7–9.
236. Mazzetti HA, Tentori MC. Breast cancer and pacemakers. *Europace* 2014;**16**:303–5.
237. Diamond JM, Kotloff RM, Liu CF, Cooper JM. Severe venous and lymphatic obstruction after single-chamber pacemaker implantation in a patient with chest radiation therapy. *Pacing Clin Electrophysiol* 2010;**33**:520–4.
238. Kypta A, Blessberger H, Lichtenauer M, Lambert T, Kammler J, Steinwender C. Gold-coated pacemaker implantation for a patient with type IV allergy to titanium. *Indian Pacing Electrophysiol J* 2015;**15**:291–2.
239. Manoušek J, Andršová I, Stejskal V, Vlašínová J, Sepši M, Kuta J et al. Hypersensitivity to material and environmental burden as a possible cause of late complications of cardiac implantable electronic devices. *Europace* 2018;**20**:e140–7.
240. Oprea ML, Schnöring H, Sachweh JS, Ott H, Biertz J, Vazquez-Jimenez JF. Allergy to pacemaker silicone compounds: recognition and surgical management. *Ann Thorac Surg* 2009;**87**:1275–7.
241. Syburra T, Schurr U, Rahn M, Graves K, Genoni M. Gold-coated pacemaker implantation after allergic reactions to pacemaker compounds. *Europace* 2010;**12**:749–50.
242. Elinav E, Leibowitz D. Constrictive pericarditis complicating endovascular pacemaker implantation. *Pacing Clin Electrophysiol* 2002;**25**:376–7.
243. Ellis CR, Rottman JN. Increased rate of subacute lead complications with small-caliber implantable cardioverter-defibrillator leads. *Heart Rhythm* 2009;**6**:619–24.
244. Bänsch D, Bonnemeier H, Brandt J, Bode F, Svendsen JH, Ritter O et al. Shock efficacy of single and dual coil electrodes—new insights from the NORDIC ICD Trial. *Europace* 2018;**20**:971–8.
245. Healey JS, Hohnloser SH, Glikson M, Neuzner J, Mabo P, Vinolas X et al. Cardioverter defibrillator implantation without induction of ventricular fibrillation: a single-blind, non-inferiority, randomised controlled trial (SIMPLE). *Lancet* 2015;**385**:785–91.