

Flutter gauche – Boucle antérieur II

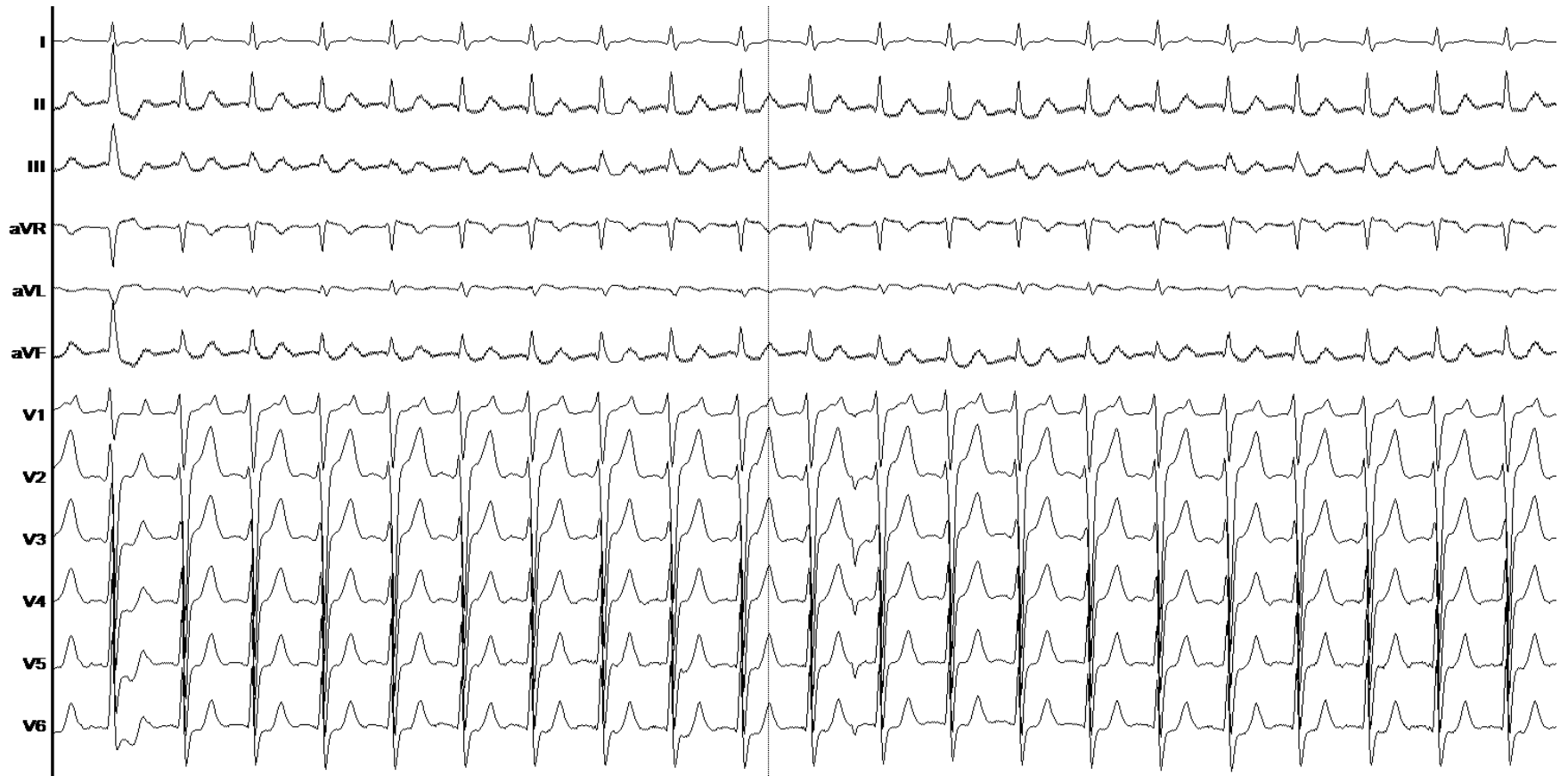Dr Durand

Janvier 2020 – Infirmierie Protestante

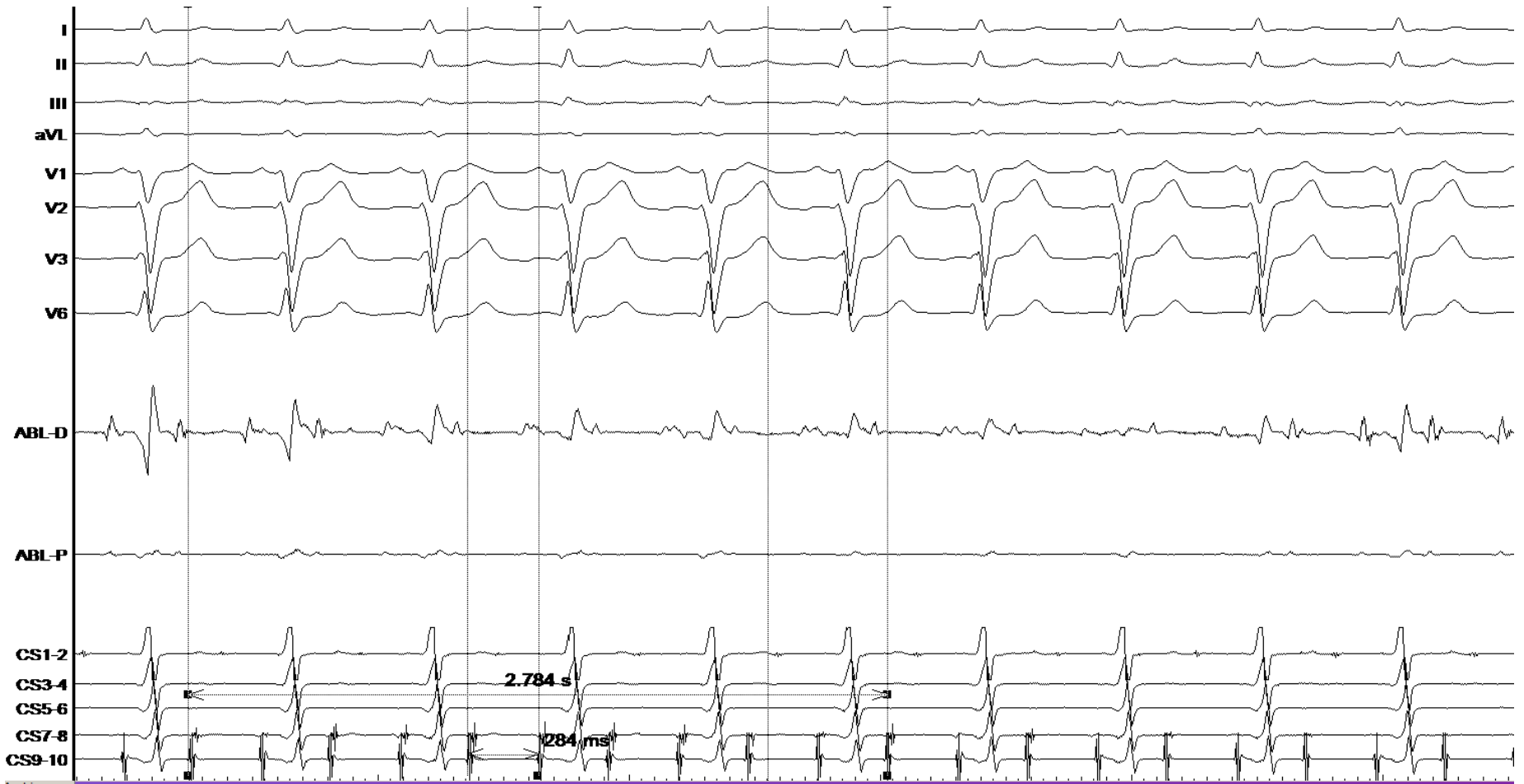MATERIEL BWI

- STSF noire D134703
- DECANAV orange R7F282CT
- PENTARAY orange D128208

ECG initial



Signaux endocavitaires

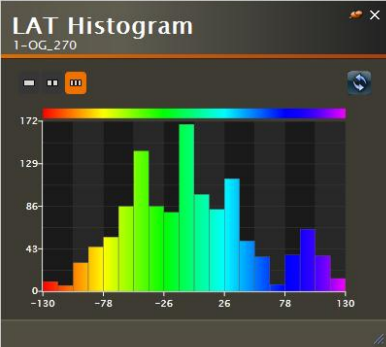


Carte d'activation

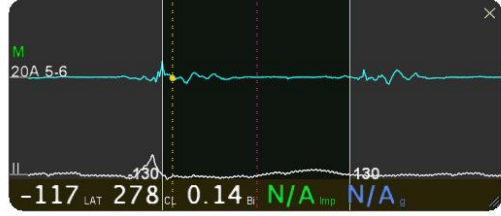
1-O_ (2351, 0) Resp

LAT Histogram

1-OG_270

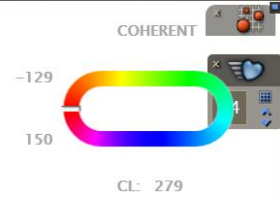


| Time (ms) | Frequency |
|-----------|-----------|
| -130 | 10 |
| -117 | 20 |
| -90 | 40 |
| -78 | 60 |
| -50 | 100 |
| -26 | 140 |
| 0 | 120 |
| 26 | 100 |
| 50 | 70 |
| 78 | 40 |
| 100 | 20 |
| 130 | 10 |

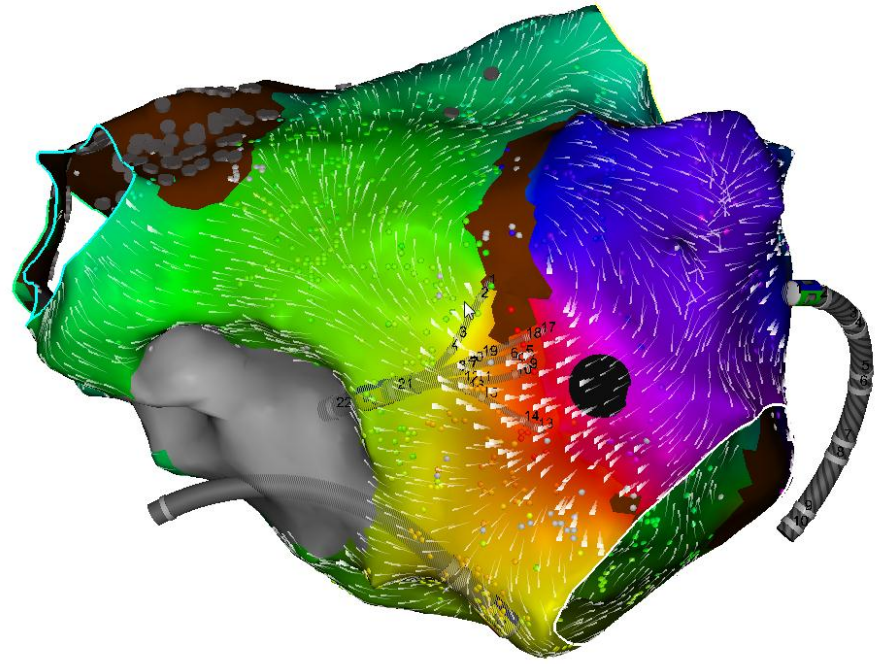


M 20A 5-6
II 130
BI 130
-117 LAT 278 CL 0.14 BI N/A_{imp} N/A_g

COHERENT




-129
150
CL: 279



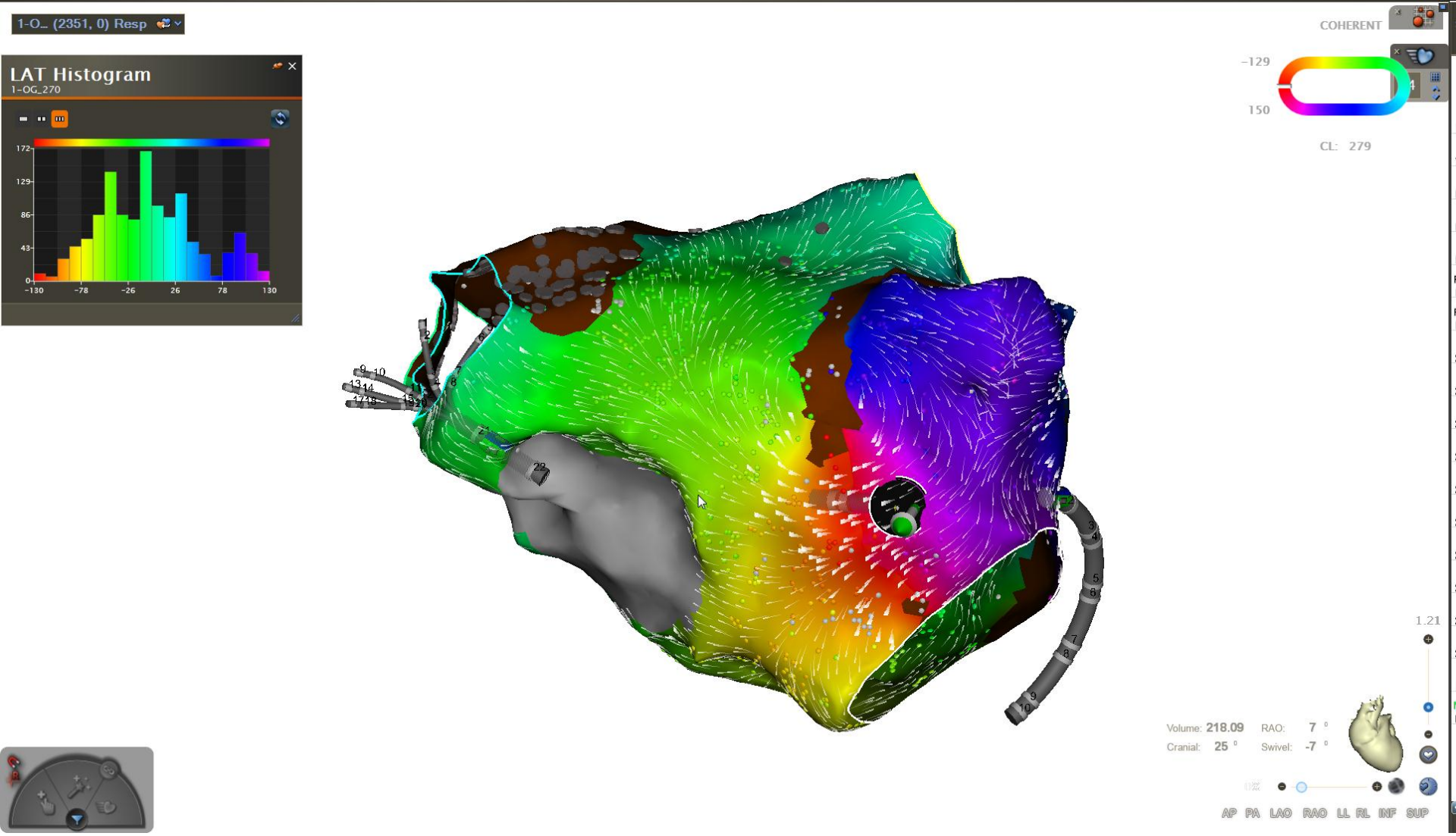
Volume: 218.09 RAO: 7°
Cranial: 22° Swivel: -3°

AP PA LAO RAO LL RL INF SUP

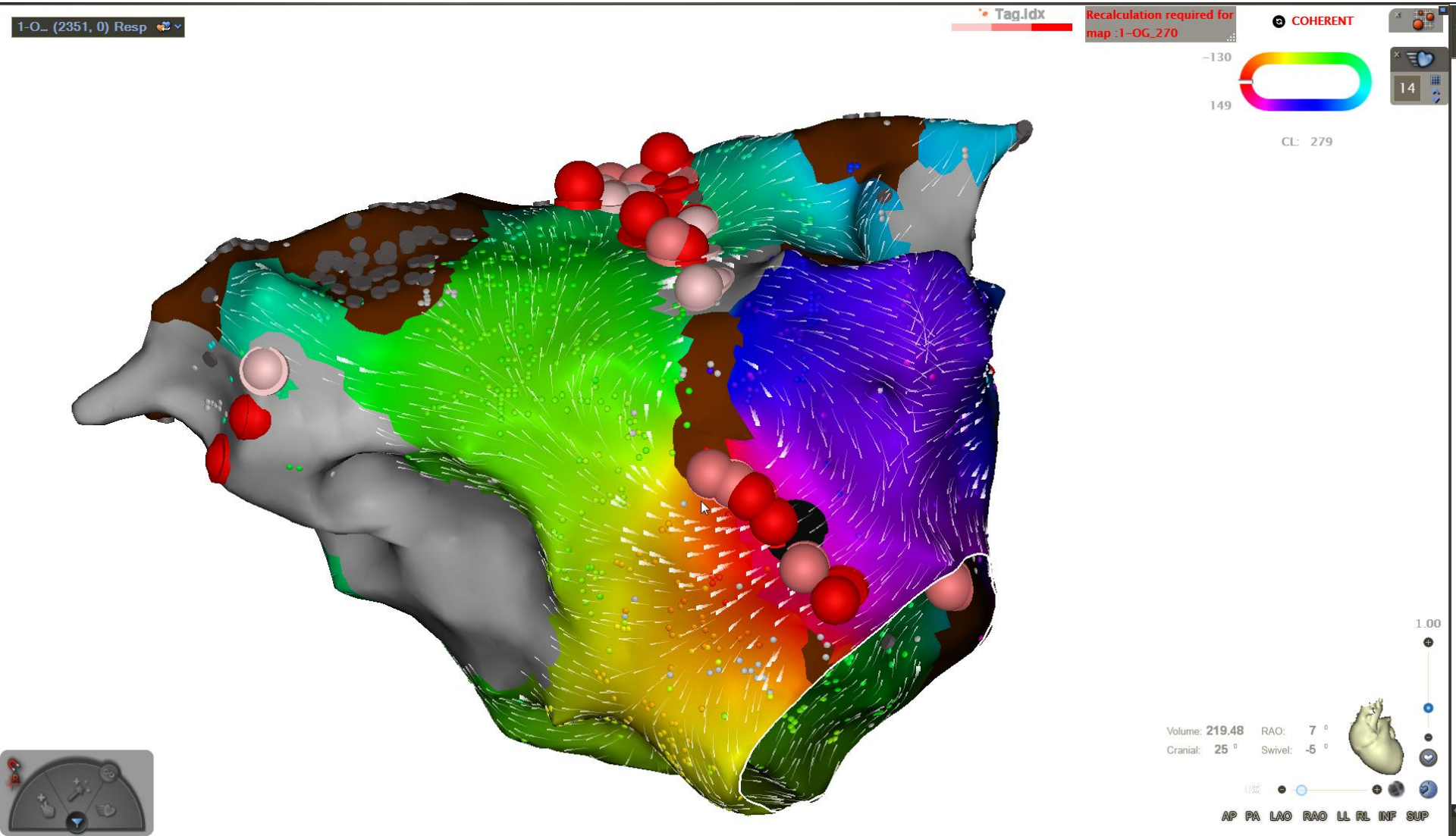
Carte d'activation



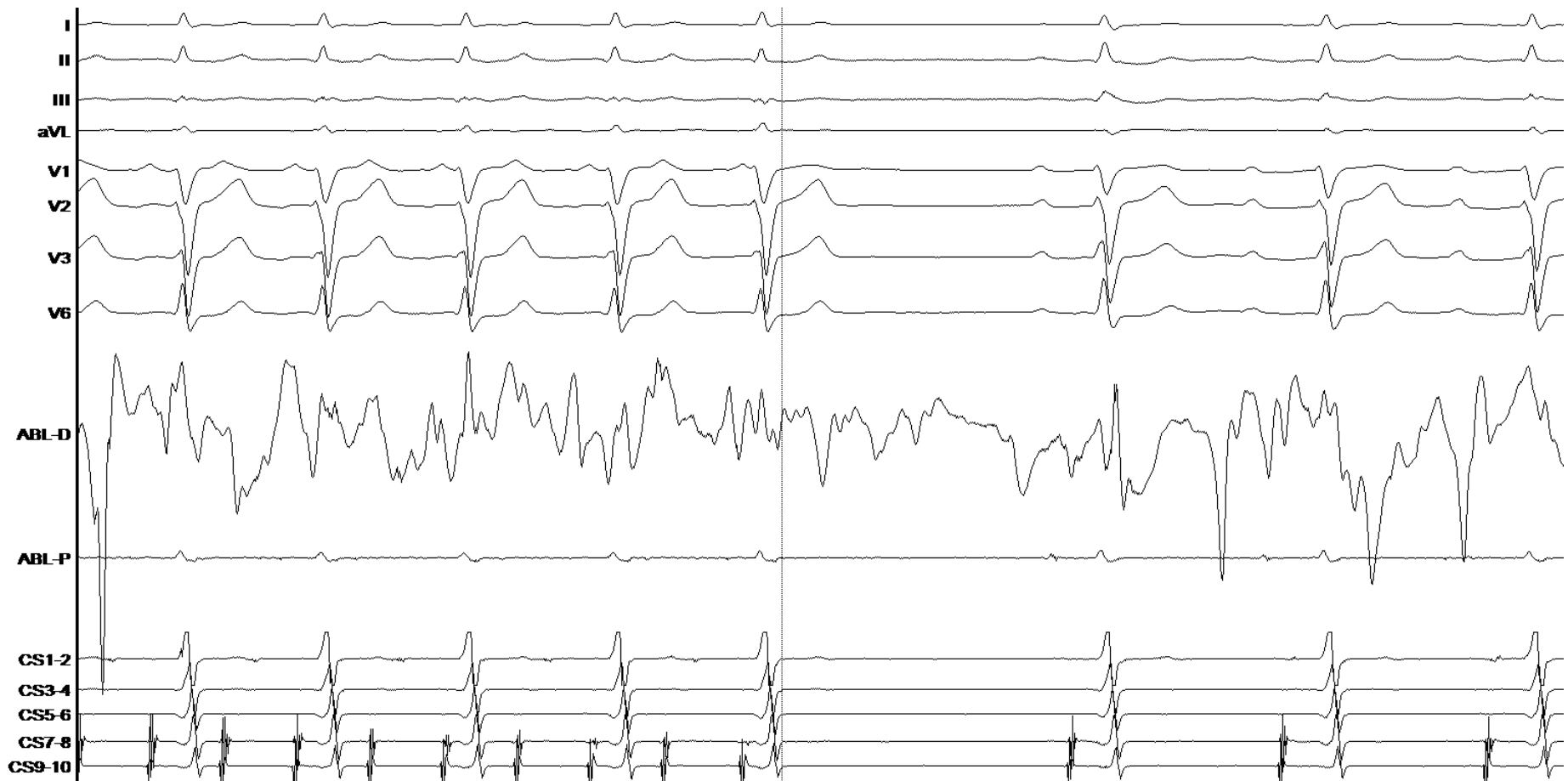
Début d'ablation



Ligne d'ablation



Retour sinusal endocaviataire



Retour sinusal ECG

