

Flutter Toit/Péri-mitral

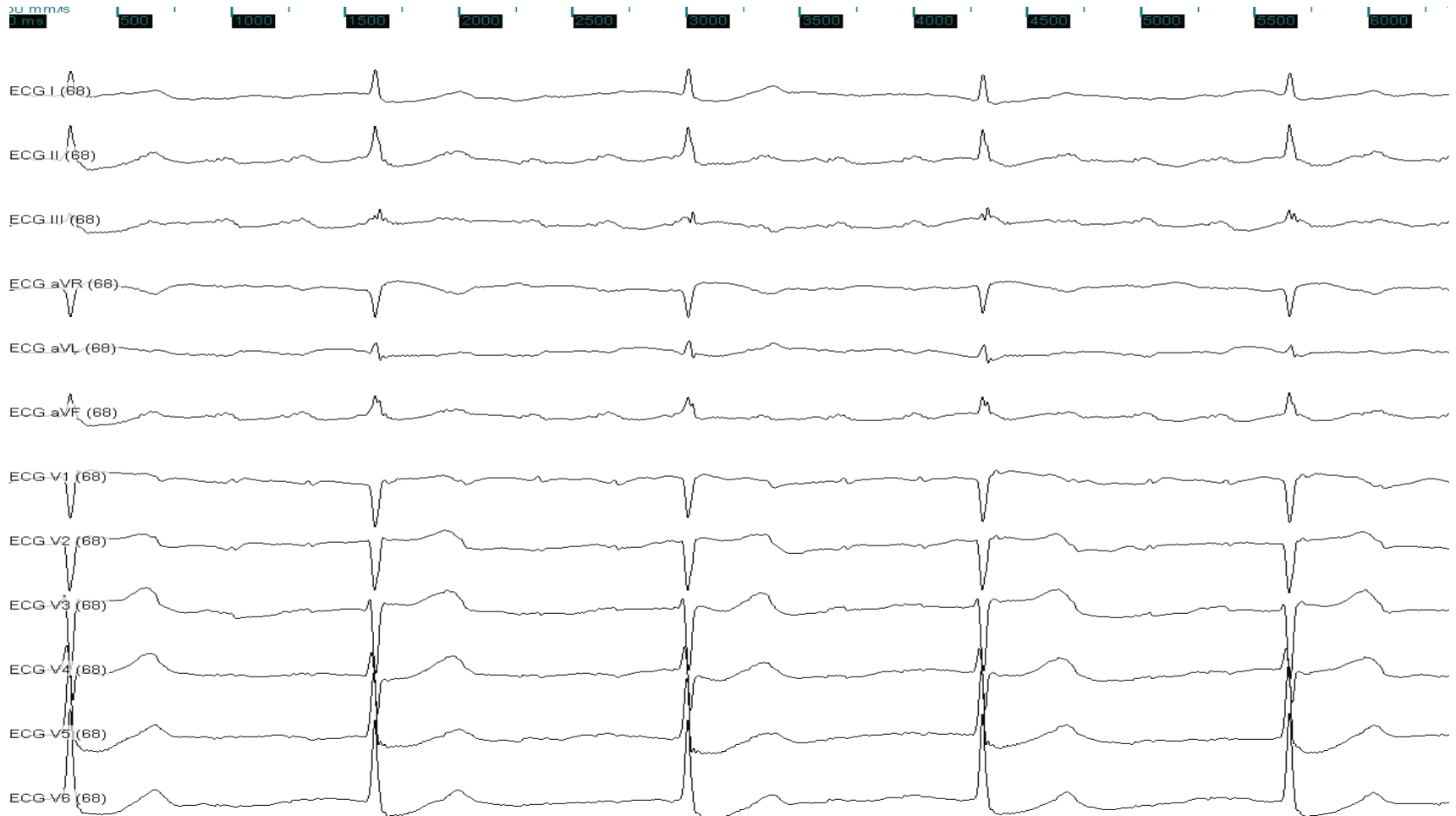
Dr Brahic

Février 2020 – Médipôle

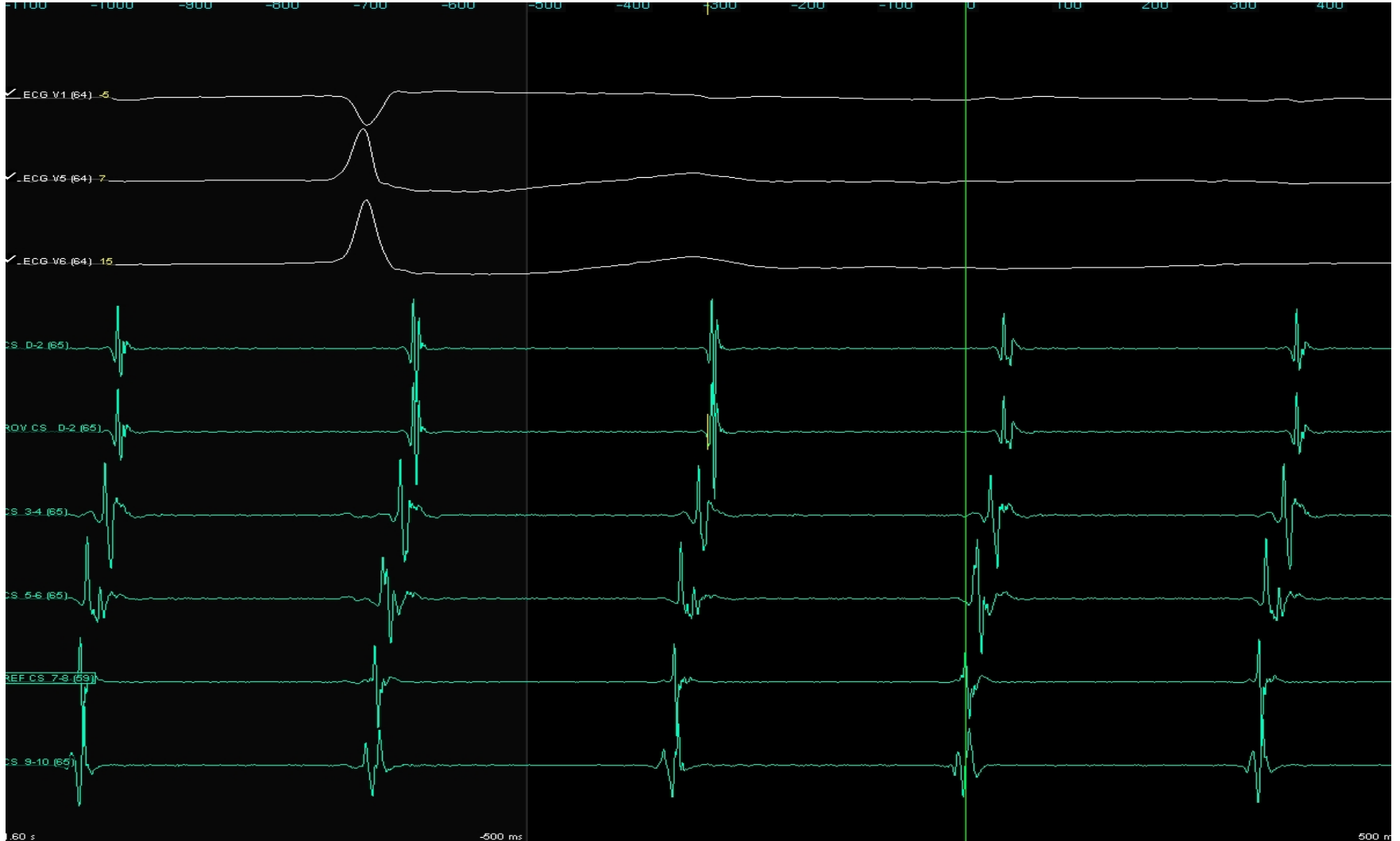Historique patient

- Première ablation : Isolation des veines pulmonaires et défragmentation de l'OG (CFE)

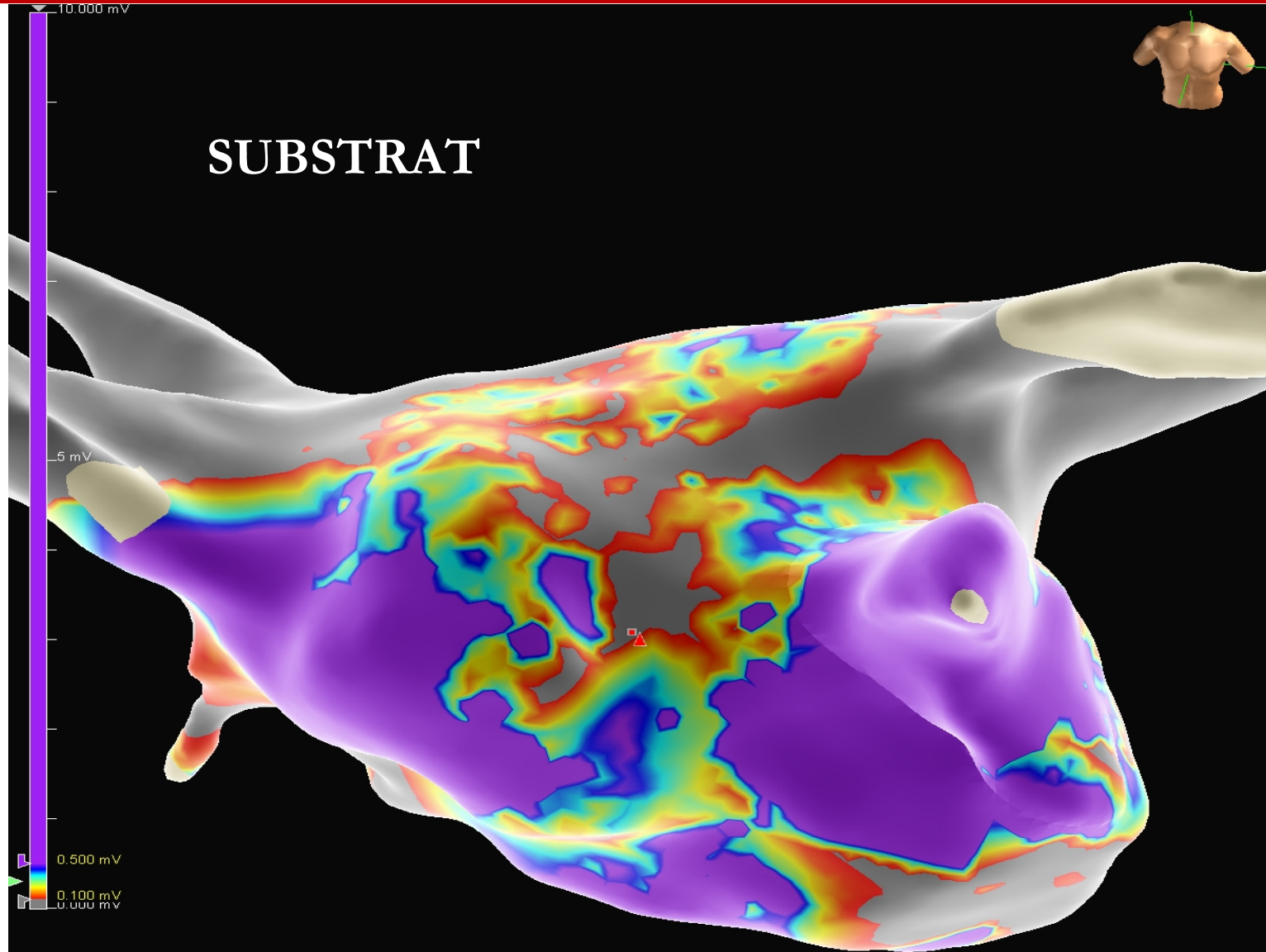
ECG début



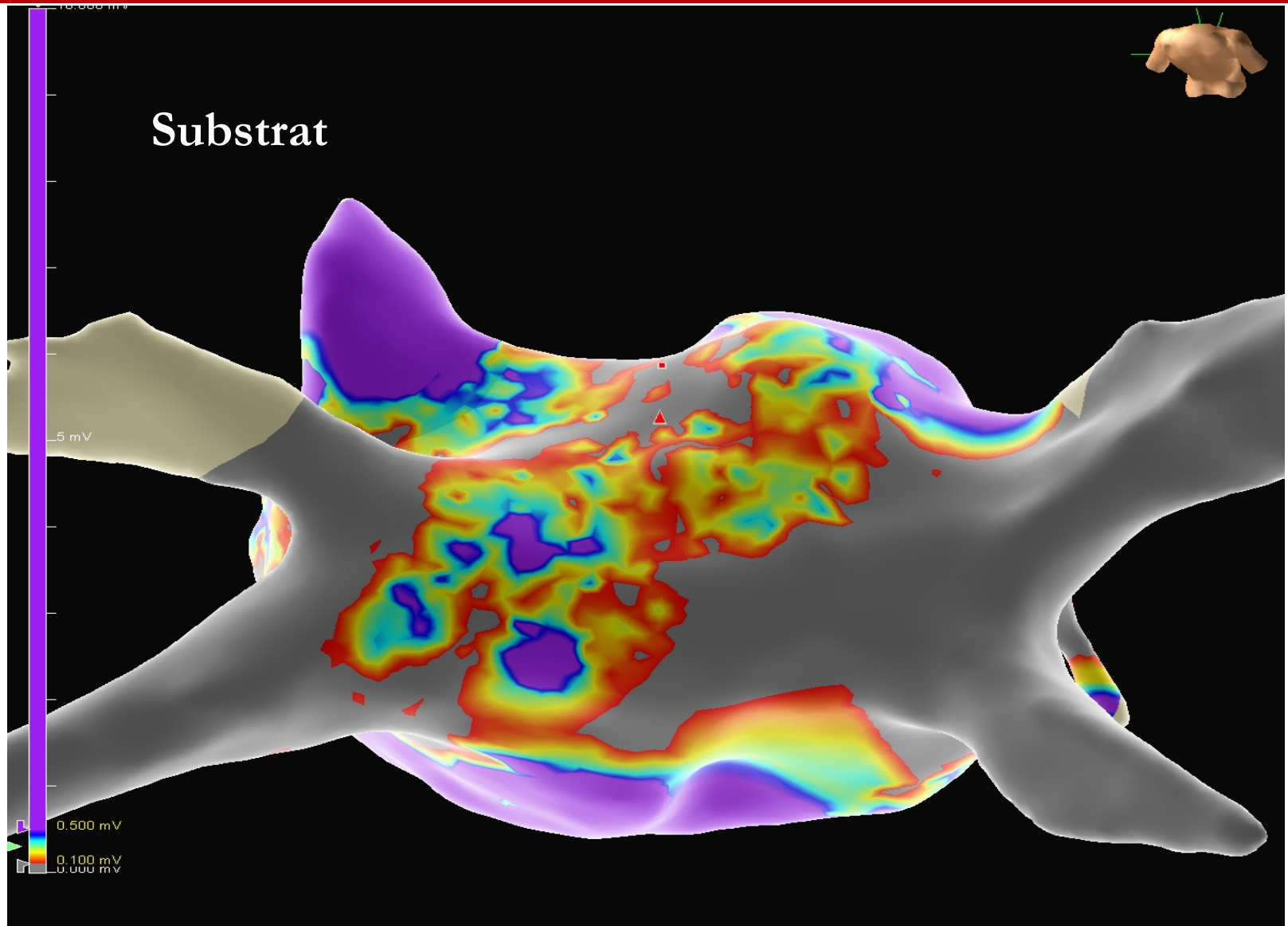
Signaux endocavitaires



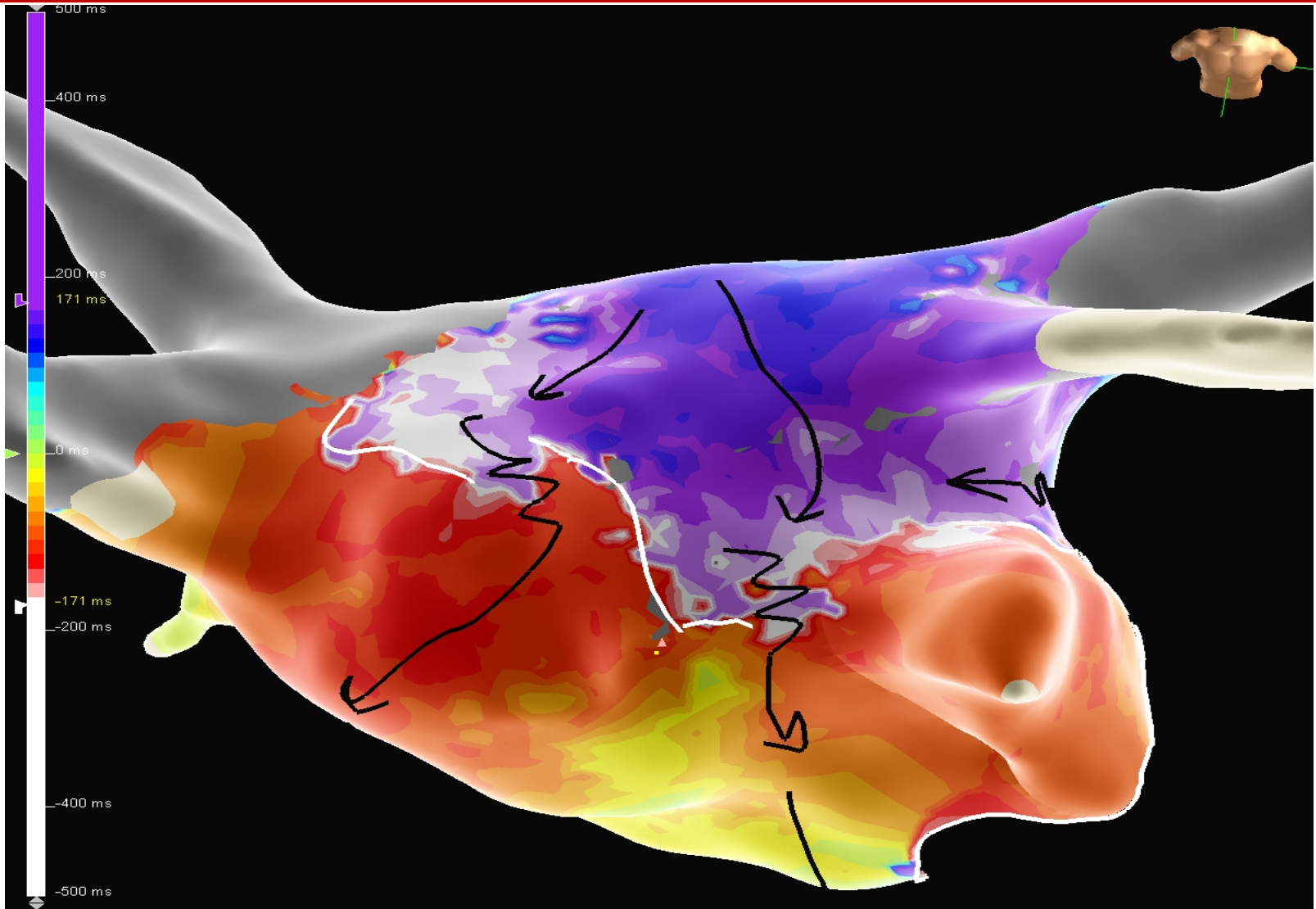
Cartographie



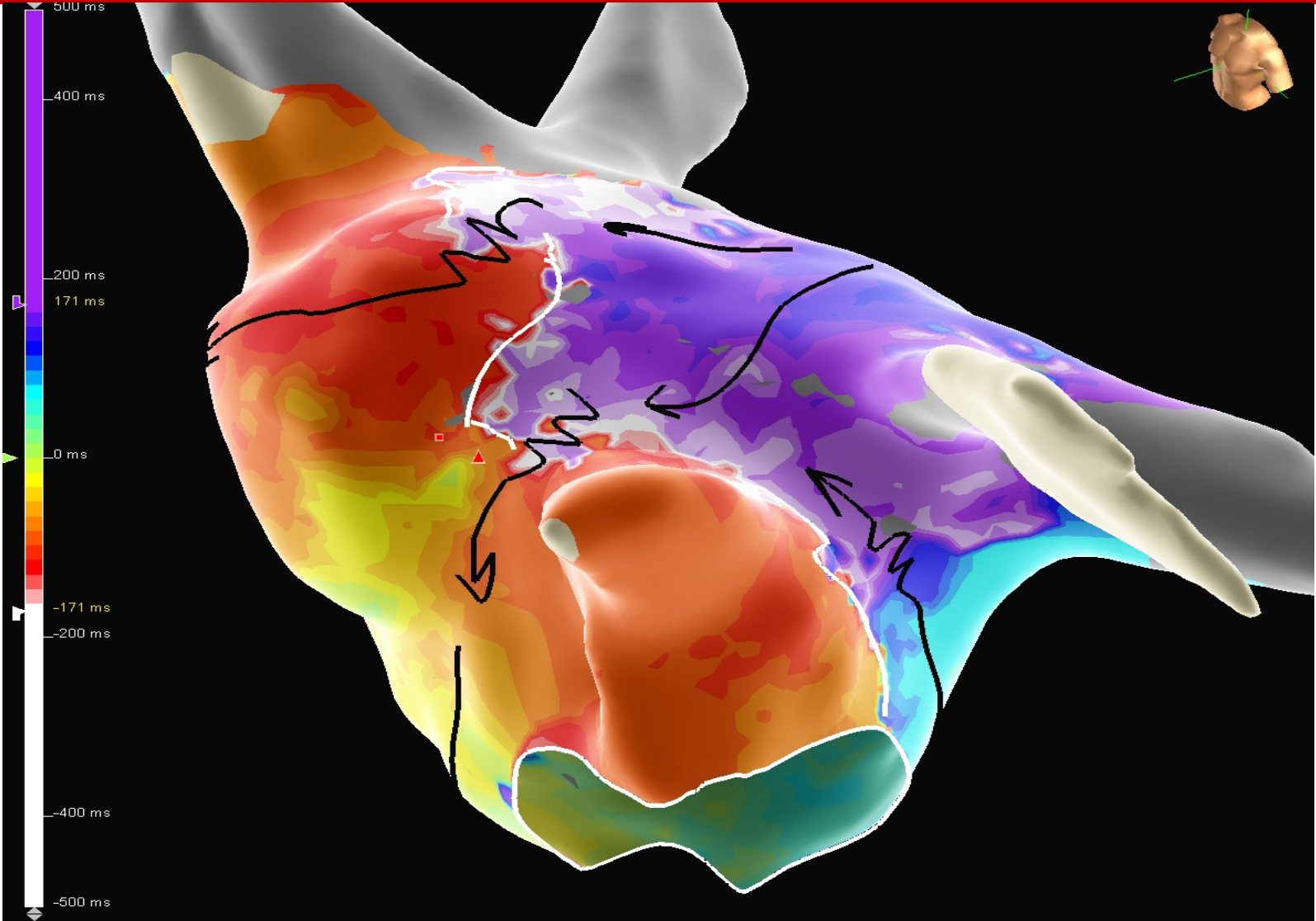
Cartographie



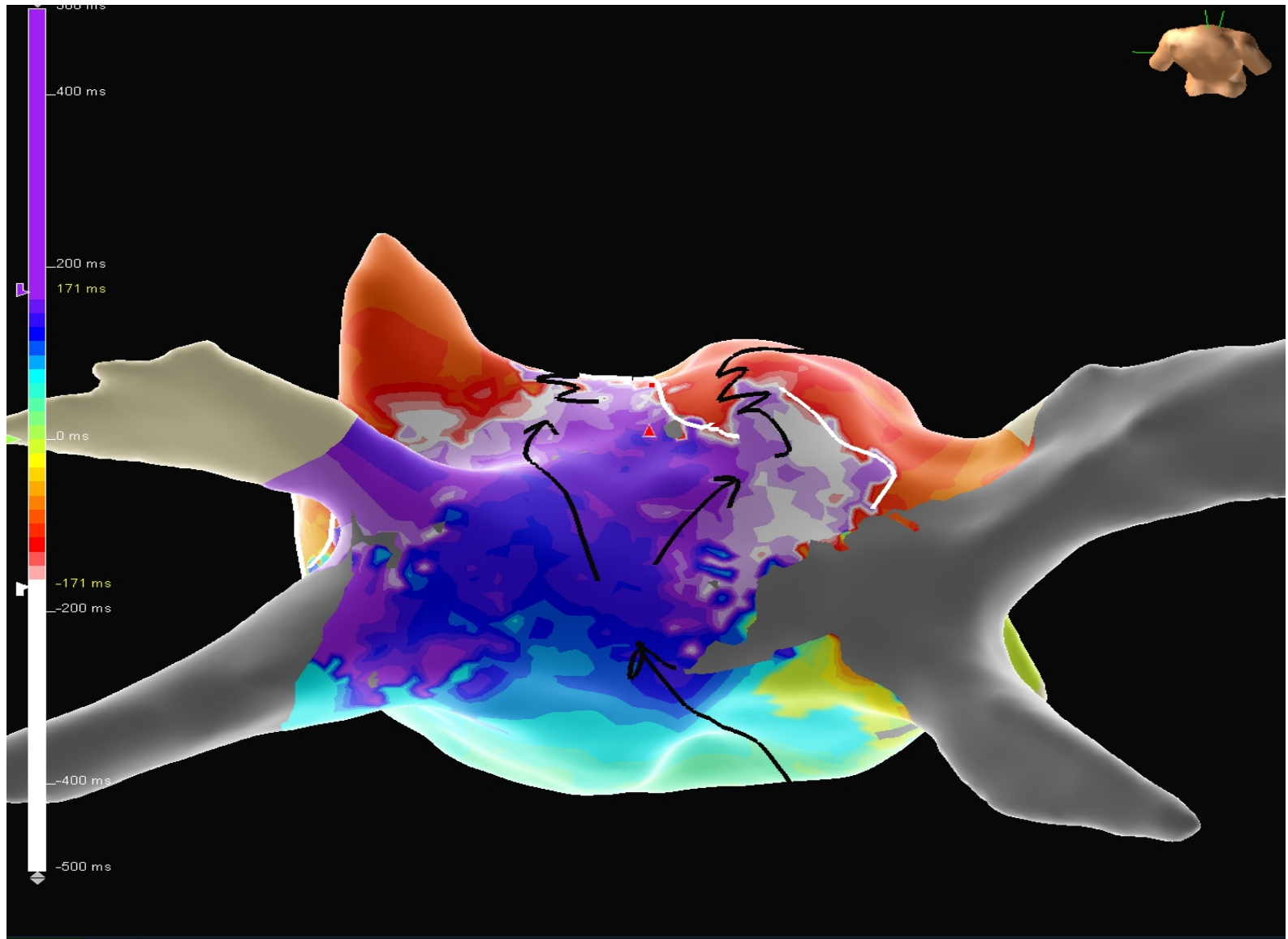
Cartographie



Cartographie



Cartographie



Cartographie

