



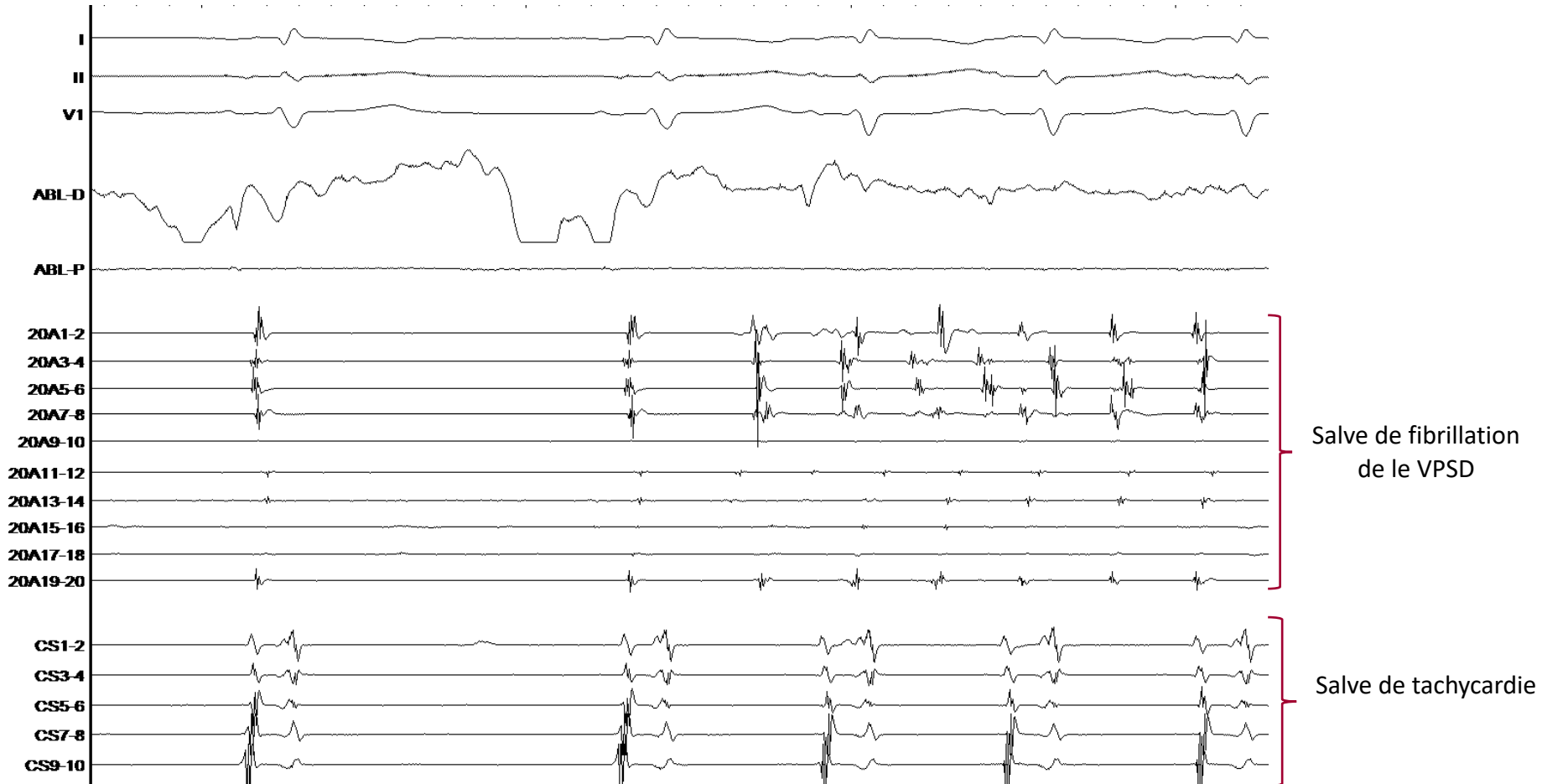
ASSOCIATION DE RYTHMOLOGIE
INTERVENTIONNELLE & STIMULATION

FA PAROXYSTIQUE ET TA UNE VEINE ACTIVE !

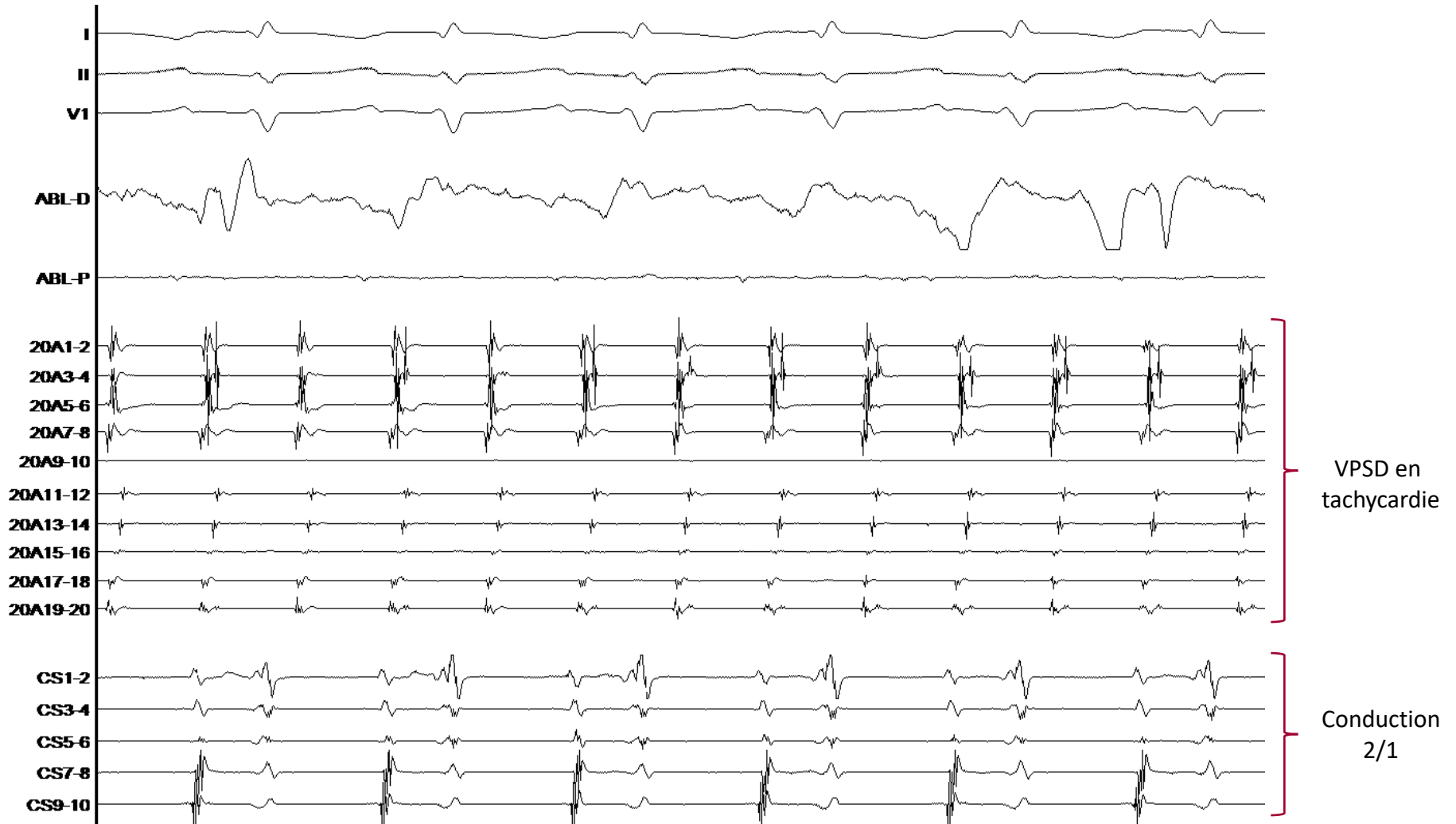
Dr Durand-Dubief – Dr Rosier

Septembre 2019 – Infirmierie Protestante

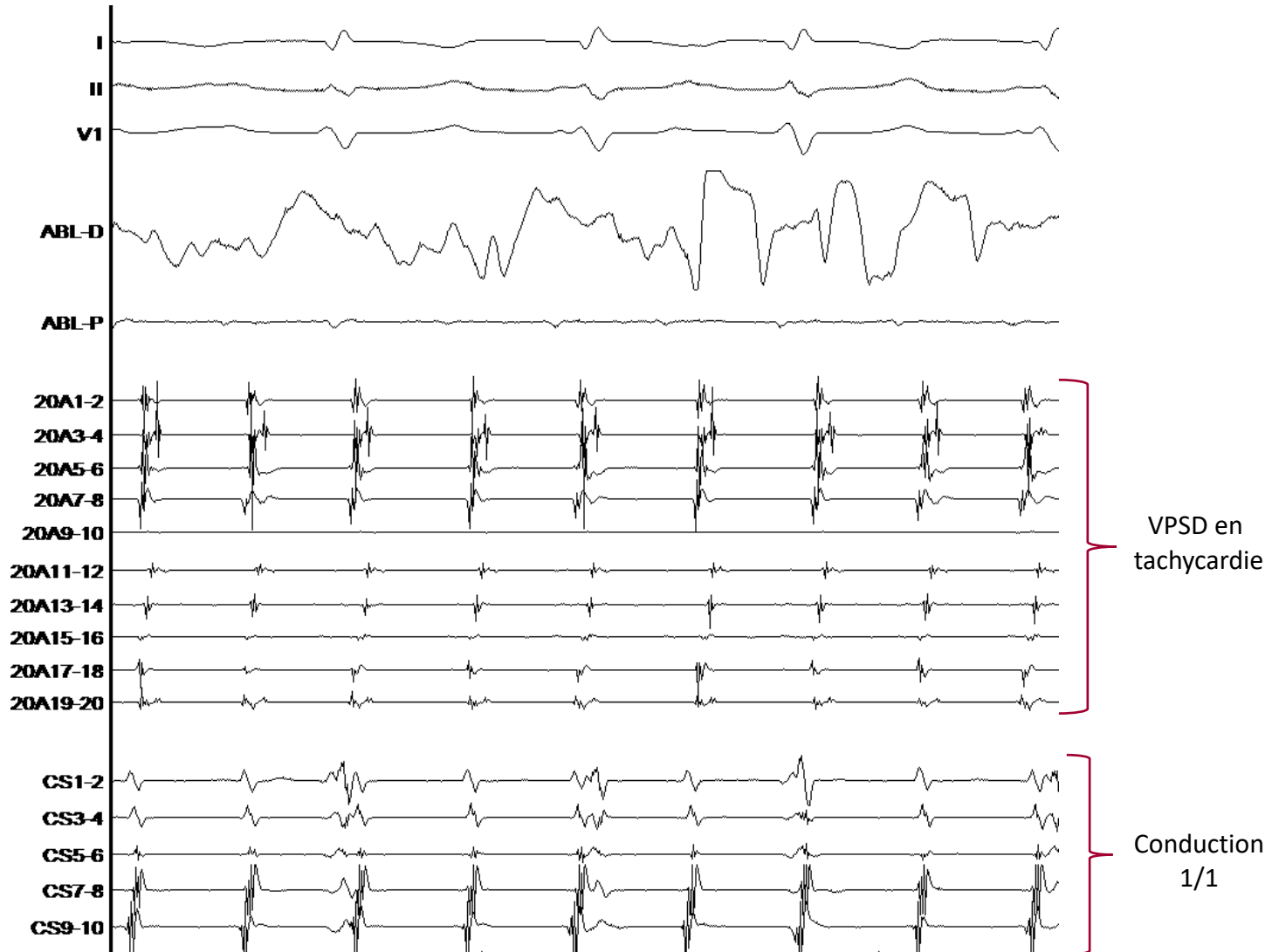
VPSD active



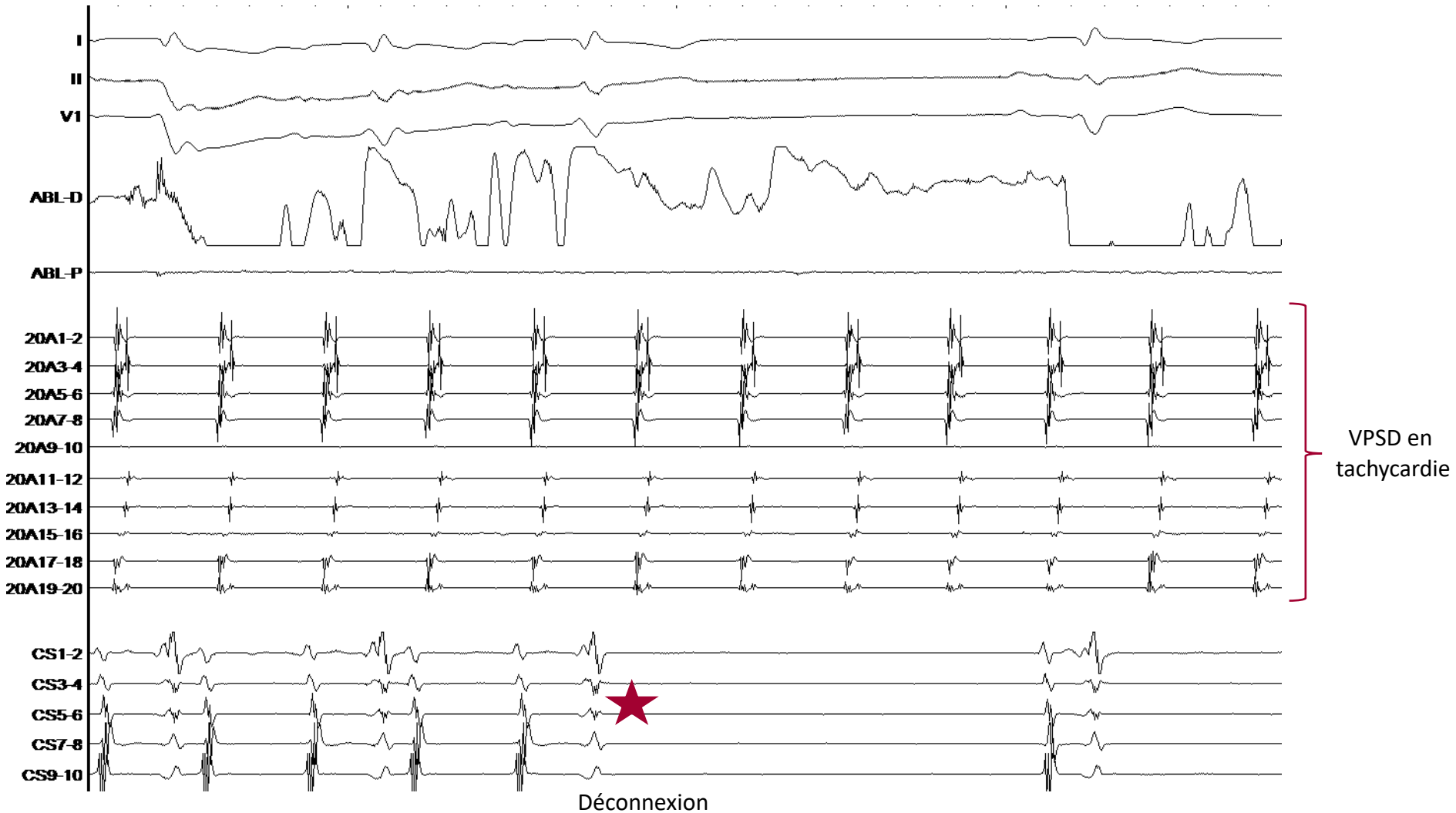
Tachycardie VPSD conduite 2/1



Tachycardie VPSD conduite 1/1



Déconnexion VPSD et retour sinusal



Fibrillation VPSD et rythme sinusal

